

9/

13-17



ICRC

3rd | INDONESIAN INTERNATIONAL SYMPOSIUM OF FORENSIC ODONTOLOGY



ICRC Seminar
March 23, 2018

Scientific Symposium
March 24-25, 2018

at Ciputra Hotel Jakarta

**PROGRAM
BOOK**

COMMITTEE

Steering Committee

- : Hartono, DDS, For.Odont.
- Prof. Elza I. Auerkari, DDS, M.Biomed, PhD, FICD, For.Odont.

Chairperson Secretary & Registration

- : Nurtami Soedarsono, DDS, PhD, For.Odont.
- : Sita Rose Nandiasa, DDS, M.Si.
- Renny Siringoringo, DDS, M.For.Sci.
- Meta Yunia Candra, DDS
- Rina Fajarwati, DDS
- Hanna, DDS
- Vanessa, DDS

Treasurer & Registration

- : Mindya Yuniastuti, DDS, MS
- Jessica, DDS

Dialson Officers

- : Tigor Rona Airlangga Harya Bima, DDS
- Sabrina, DDS
- Angger Waspodo, DDS
- Sela Natasha
- Larissa Permata Shany
- Bilqis Nurul Azizah
- Layli Pinarining Gusti

Equipment

- : Rizki Tanjung, DDS, M.M., M.Si
- Risco Taufik Achmad, BDS

Scientific Meeting

- : Alphonsus R. Quendangen, DDS, DFM, For.Odont
- Bosco
- Darwin Yunaidy

Scientific Board

- : Maslari Novita, DDS, M.Kes, PhD, For.Odont.
- Peter Sahelangli, DDS, DFM, For.Odont.
- Dian Retno Utari, DDS

The Role of Dental Radiography in Aviastar Airplane Crash Victim Identification (Case Report)

Muliaty Yunus^{1*}, Hasanuddin Thahir², Tjiang Sari Lestari³, Putri Wulansari¹, Irwan Setiawan¹

¹Radiology Department, Faculty of Dentistry Hasanuddin University

²Periodontology Department, Faculty of Dentistry Hasanuddin University

³Forensic & Medicolegal Department, Faculty of Medicine Hasanuddin University

*Corresponding author: Muliaty Y, muldul.1325@gmail.com

Background: It is often difficult to identify victims of an airplane crash since in most cases, the victims have been severely burned or badly dismembered. In such conditions, one of many methods of identification is dental analysis. This is because human teeth are resistant to very high temperature and they will remain intact although other body parts have already been damaged. Dental identification through ante-mortem and post-mortem radiological imaging can be performed using superimposition technique. Ante mortem dental X Ray is one of the important primary evidence. However during identification process the dentist need a handheld X-Ray apparatus which must be lightweight, safe, economical and practical to take X Ray post mortem of the victim. **Method:** Radiographic superimposition technique for dental identification is a process of victim identification by placing ante-mortem dental imaging over the post-mortem one and looking for the similarities between the two images to establish a positive identification. Using this method 2 victim out of 11 victims were able to be identified positively. The other victims was identified through another method of identification. **Conclusion:** Identification of airplane crash victims can be done by dental analysis, which is performed by radiographic superimposition method between the ante-mortem and post-mortem radiological images. In DVI operations, it is best to use a handheld x-ray system with practical, lightweight, and cordless design to improve dental radiology speed, convenience, and efficiency.

Keywords: identification, dental radiography, superimposition

CASE REPORT
THE ROLE OF DENTAL RADIOGRAPHY IN AVIASTAR AIRPLANE CRASH VICTIM IDENTIFICATION

Muliaty Yunus, Hasanuddin Thahir*, Tjiang Sari Lestari**, Irene Edith Rieuwpassa*, Dwi Putri Wulansari**

**Department of Forensic & Medicolegal, Faculty of Dentistry, Hasanuddin University, Makassar*

***Department of Forensic & Medicolegal, Faculty of Medicine, Hasanuddin University, Makassar*

Background

- Identification process on victims of airplane crash is difficult due to several conditions such as severe burn and dismembered body parts.
- One of the identification methods that can be used is dental identification, since human teeth are able to endure high temperature, making them intact even though other body parts are shattered
- Dental identification through dental radiography is performed by Craniofacial Superimposition Technique, which is to compare ante-mortem and post-mortem dental x-ray.
- Dental radiography as ante-mortem data is a crucial primary data. During the identification process, forensic odontologists need dental x-ray equipment that is light, safe, inexpensive, and practical to perform post-mortem radiological examination.

Objectives

To identify victims of airplane crash disaster with severe burn and cannot be identified visually by using dental radiography superimposition technique.

Case

An Aviastar airplane has been reported to fall at Mount Bajaja, Desa Ulu Salu, Kabupaten Luwu Utara, South Sulawesi at 2nd October 2015, 2.25 pm. There were 7 passengers and 3 flight crew, and all of them were reported dead with severe burn. DVI team from Bhayangkara Police Hospital collaborated with Forensic team from Faculty of Medicine and Faculty of Dentistry Hasanuddin University to perform victim identification.

Ante-mortem data was collected from family and relatives, and were compared with post-mortem data. There was one dental panoramic photo which belonged to a 45-year-old male among the ante-mortem data. This ante-mortem dental radiography was compared to post-mortem dental radiography using dental radiography superimposition method.

Identification Method

Dental radiography superimposition is a process of identification by overlaying ante-mortem and post-mortem x-ray photos. The data are matched by evaluating their anatomical similarity of the dental profile.

Materials & Instruments

- Dental X-Ray Mobile Digital unit
- Laptop
- Ante-mortem dental panoramic x-ray (softcopy)
- Plastic sheet
- Toothbrush.

Identification Process

A. Collecting post-mortem dental radiography

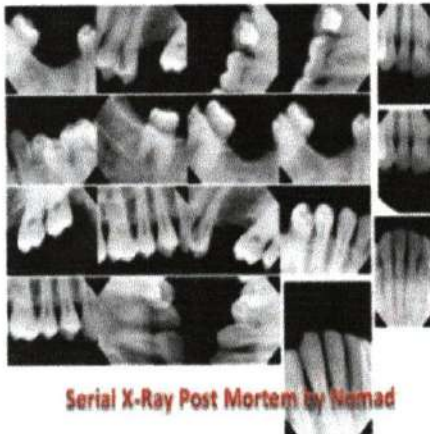
1. Teeth (maxillary and mandibular) were cleaned thoroughly using a toothbrush
2. Dental radiography was taken using periapical technique
 - a. Upper jaw (maxillary teeth)
 - The skull was positioned until the occlusal surface of the maxillary teeth is parallel to the floor
 - X-ray sensor was placed on the region that would be photographed
 - Expose to all regions.
 - b. Lower jaw (mandibular teeth)
 - The skull was positioned until the occlusal surface of the mandibular teeth is parallel to the floor
 - X-ray sensor was placed on the region that would be photographed
 - Expose to all regions.

B. Dental radiography superimposition process

Superimposition process was performed digitally by overlaying post-mortem dental radiography with ante-mortem dental x-ray and matching general features from both data. Next step was reduced the opacity of the overlaying photograph to show the features of the other photograph.

The similarity was evaluated by checking the dental anatomical resemblance from both overlaying dental radiography.





Serial X-Ray Post Mortem by Namad



Superimposition Data

Conclusion

Victim identification can be performed through dental analysis using radiographic superimposition. Radiographic superimposition is able to identify victims with severe damage such as burn, decomposition, and skeletonization. This technique is effective and efficient for identifying a large number of disaster victim. Therefore, dental radiography superimposition method is one of the ideal methods to identify victims of disasters.

Bibliography

1. Cevidanes LHS, Styner MA, Proffit WR. Image analysis and superimposition of 3-dimensional cone-beam computed tomography models. *Am J Orthod Dentofac Orthop* 2006 May; 129(5): 610-8.
2. Franklin D, Swift L, Flavel A. 'Virtual anthropology' and radiographic imaging in the forensic medical sciences. *Egyptian Journal of Forensic Sciences* 2016; 6: 31-43.
3. Forrest AS. Collection and recording of radiological information for forensic purposes. *Australian Dental Journal* 2012; 57(1 Suppl): 24-32.
4. Latham K, Bartelink E, Finnegan M. Advance in the use of craniofacial superimposition for human identification. In: Milligan CF, Finlayson JE, Cheverko CM, Zarenko KM. *New perspectives in forensic human skeletal identification*. London: Sara Tenney; 2018. p. 241-64.
5. Pathak AK, Mangal HM. Role of superimposition technique in practice of forensic medicine. *JPAFMAT* 2006; 6: 45-7.
6. Sakuma A, Makino Y, Saitoh H, Chiba F, Ishii N, Iwase H. Evaluation of a personal

identification method using the fusion function of CT images and dental radiographs.
Dentomaxillofacial Radiology 2015; 44: 1-6.

7. Tinoco RLR, Martins EC, Daruge EJ, Daruge E, Prado FB, Caria PHF. Dental anomalies and their value in human identification: a case report. J Forensic Odontostomatol 2010; 28(1): 39-43.

Presented at : 3 rd Indonesian International Symposium of Forensic Odontology
Ciputra Hotel Jakarta Barat Indonesia
March 24 -25,2018