



Characteristics Vertical Position of Mental Foramen Reviewed by Panoramic Radiography as a Guide in Predicting Individual's Age on Forensic Odontology Examination

Muliaty Yunus¹, Muhammad Harun Achmad², Dwi Putri Wulansari¹, Rifaldi Haeruddin³

¹Lecturer, Department of Dental Radiology, Faculty of Dentistry, Hasanuddin University, Makassar, Indonesia.

²Lecturer, Department of Pediatric Dentistry, Faculty of Dentistry, Hasanuddin University, Makassar, Indonesia.

³Undergraduate Student, Department of Dental Radiology, Faculty of Dentistry, Hasanuddin University, Makassar, Indonesia.

Author to whom correspondence should be addressed: Harun Achmad, Pediatric Dentistry Department, Faculty of Dentistry, Hasanuddin University, Makassar, South Sulawesi, Indonesia. Phone: +62 85242739400. E-mail: harunachmader@gmail.com.

Academic Editors: Alessandro Leite Cavalcanti and Wilton Wilney Nascimento Padilha

Received: 19 January 2018 / Accepted: 11 May 2018 / Published: 25 May 2018

Abstract

Objective: To know the characteristics vertical position of mental foramen based on panoramic image as a guide in predicting the individual's age for the purposes of Forensic Odontology examination. **Material and Methods:** The method of this study was observational and descriptive by using the cross-sectional approach. The data is obtained from the secondary data, which is adopted by purposive sampling technique in RSGM FKG Hasanuddin University and RSUD Batara Guru Belopa, District Luwu, Indonesia. Data was analyzed by using descriptive analysis method. **Results:** Vertical position of mental foramen is mostly affected by age, but there are some cases where the Vertical position of mental foramen is not affected by the individual's age. Before the eruption process of permanent tooth finish, mental foramen is located closer with alveolar ridge. After the eruption process of permanent tooth, slowly mental foramen is moving halfway to the lower border of corpus mandible. As each individual grows older and resorption process occurs to alveolar bone, mental foramen will appear moving closer to alveolar ridge. **Conclusion:** The process of identifying mental foramen to predict individual's age in the relation with forensic odontology is possible to be done by using roentgen image in mandible of the dead victim. Although it still requires further identification, mental foramen position can be one of the references in predicting individual's age.

Keywords: Forensic Anthropology; Forensic Dentistry; Radiography, Panoramic.

Introduction

In the case of forensic examination where an individual cannot be recognized, predicting the victim's age can be used as a guide in identifying the victim. This is one of the reason why a more in-depth study to find individual's age identity with specific technique is needed. The growth and development of human body structure tend to be fixed and almost always the same for all people, therefore these factors can be linked to predict individual's age. Age prediction is applicable to both living and died individuals [1].

Anatomy varieties can be found in human bodies, whether in its structure of blood vessels, muscle, bones, also skull structure. Mental foramen represents one of the anatomy structures in human that is passed by arteries and nerves [2]. The use of panoramic radiography in identifying mental foramen gives more advantages such as providing thorough second jaw image, inexpensive, and the radiation received by individuals are lower than Computed Tomography Scan (CT-Scan) [3,4].

Generally, mental foramen can be found in the vicinity of mandible premolar root. Its position is toward premolar tooth root is varied. Mental foramen usually located below, in line, or above premolar apex tooth [5]. Based on its context with horizontal tooth apex, mental foramen can be divided as follow [6,7]: a) Position 1 located in line with the first premolar of mandible; b) Position 2 located between the first premolar and second premolar of mandible; c) Position 3 located in line with the second premolar of mandible; and d) Position 4 located between the second and the first premolar of mandible.

Vertically, mental foramen can also be affected by individual's age. In their childhood, before deciduous tooth erupted, mental foramen located near close to the alveolar ridge (Position 1) [2]. During the eruption period of deciduous tooth, until its position become permanent and moving to the middle of mandible (Position 2) and moving to the lower border of mandible (Position 3) after all teeth erupted [2].

For the elderly, the occurrence of resorption on mandible bone will bring mental foramen closer to the alveolar ridge border. When all teeth have fallen off (edentulous), mental foramen will be found quite close with Alveolar Ridge. In the severe resorption condition, mental foramen will be gone and replaced with concave which located in every mandible surface [2].

Therefore, this study aimed to know the characteristic vertical position of mental foramen based on panoramic image as a guide in predicting the individual's age for the purposes of Forensic Odontology examination.

Material and Methods

Study Design

The study used secondary samples in the form of secondary data from the patient's panoramic image result in line with specific inclusion criteria that had already been determined. This study was an observational and descriptive study using cross sectional approach.

Data Collection

The identification process of vertical position of mental foramen used conventional measurement and type division from its vertical position based on guidance from several references. Sample technique collection of this study used purposive sampling technique.

The sample of this research was in the form of secondary data from the patient's image treated in Radiology Department, Faculty of Dentistry, Hasanuddin University in 2016-2017 and Batara Guru Hospital in 2012-2017.

Sample Criteria

Inclusion criteria: panoramic radiography image data of the patients treated in Radiology Department, Faculty of Dentistry, Hasanuddin University in 2016-2017 and Batara Guru Hospital in 2012-2017.

Exclusion criteria: 1) Patients were below 12 years of age and or the two teeth of premolar mandible had not erupted yet; 2) Patients aged over 80 years old and or experience severe alveolar bone resorption; 3) Patients who experience expanding pathology condition in both area of mandible which causes radiolucent image on its radiography image and 4) Patients with panoramic image that could not be used to identify its mental foramen in mandible area.

Total 98 Panoramic images data from two hospitals in different stages during certain period of time meets the inclusion area, which is determined by the researcher.

Statistical Analysis

The data from this study was processed using SPSS (Statistical Package for Social Sciences), Version 16.0 (IBM Corporation, Chicago, IL, USA).

Ethical Aspects

Ethical permission was granted by Ethics Committee from Medical Faculty, Hasanuddin University.

Results

There are many variations of vertical position of mental foramen on human based on age category. Based on the Table 1, it could be seen that at the age of 12-16 years old, vertical position of mental foramen mostly could be found in position 2 (it was located in the middle of mandible corpus, equal between above and lower border) totaling 57.1%, next was position 3 (it were located closer to the lower border of mandible corpus) totaling 42.9%.

In the category of 17-25 years old, vertical position of mental foramen mostly could be found in position 3 (54.2%), position 2 (25%) and lastly position 1 (it was located in the upper border of mandible corpus near close to alveolar ridge) totaling 20.8%. In the category of 26-35 years old,

vertical position of mental foramen mostly could be found in position 3 (59.3%), next were position 2 (37%), and last were position 1 (3.7%).

In the 36-45 year old category, vertical position of mental foramen mostly could be found in position 3 (55%), next were position 2 (35%), and lastly position 1 (10%). In the age category of 46-55 years old, the foramens were located vertically. The most common mental encountered were a numbered position 78.6%, next were position 2 (14.3%), and last were positioned with 7.1%.

In the age category of 56-65 years old, vertical position of mental foramen mostly could be found in position 3 (60%), next were position 2 (40%). While for the age of 65 years old, vertical position of mental foramen mostly could be found in position 1 (100%).

Table 1. Variations of vertical position of mental foramen on human based on age category.

Age (in Years)	Foramen Position						Total	
	1		2		3		N	%
	N	%	N	%	N	%		
12-16	0	0.0	4	57.1	3	42.9	7	100.0
17-25	5	20.8	6	25.0	13	54.2	24	100.0
26-35	1	3.7	10	37.0	16	59.3	27	100.0
36-45	2	10.0	7	35.0	11	55.0	20	100.0
46-55	1	7.1	2	14.3	11	78.6	14	100.0
56-65	2	40.0	0	0.0	3	60.0	5	100.0
> 65	1	100.0	0	0.0	0	0.0	1	100.0
Total	12	12.2	29	29.6	57	58.2	98	100.0

From 98 samples of radiography images, vertical position of mental foramens were mostly located in position 3 (58.2%), followed by position 2 (29.6%) (Table 2).

Table 2. Distribution of mental foramen position.

Foramen Position	N	%
1	12	12.2
2	29	29.6
3	57	58.2

It was found that in the period of the permanent tooth eruption in the category of 12-16 years old of age, mental foramens were mostly found in position 2 which located in the middle of mandible corpus, equal between the upper and lower border with total number of 57.1%. This case was in line with the theory, which stated that before the permanent tooth erupted, vertical position of mental foramen located near close with the alveolar ridge and slowly will moving further from alveolar ridge as the time for the eruption of permanent tooth begins.

While in the age category of 17-25 years old, 26-35 years old, 36-45 years old, and 46-55 years old, it was found that vertical position of mental foramen mostly located in position 3 which located near to the lower border of mandible corpus (Figures 1 and 2) This was in line with the theory which states that in the eruption period of permanent tooth, mental foramen vertical position is getting further from alveolar ridge and getting closer with the lower border of mandible corpus.



In the fourth age category, it was also found some samples where mental foramen located in position 1 which was located near the alveolar ridge. It was matched with the theory which stated that when individual is in their old age, the mental foramen was slowly getting closer with alveolar ridge due to the alveolar bone resorption process.

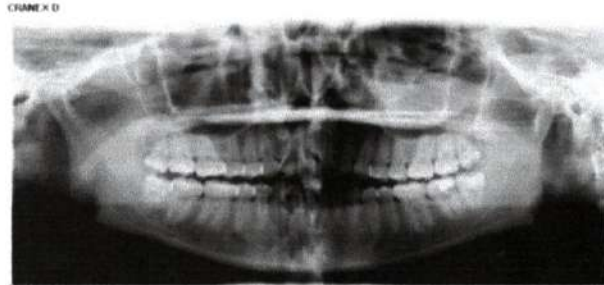


Figure 1. Third Position of mental foramen (patient 24 years old).

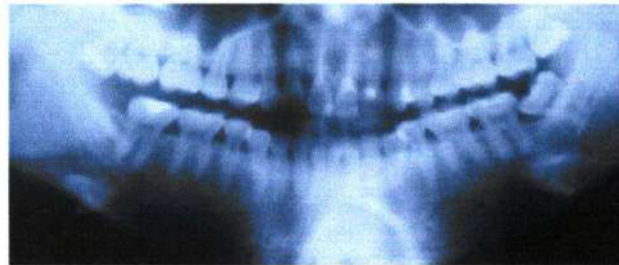


Figure 2. Mental foramen position (patient 36 years old).

Lastly, at age of 46-55 years old, and age >65 years old, there were many samples where the mental foramen vertically located in the position. One position where mental foramen was located near alveolar ridge. It was in line with a theory, which stated that in the old age, the resorption process of alveolar bone occurred rapidly, which caused the mental foramen appeared back close to the alveolar ridge. Moreover, mental foramen was often cannot be identified because of this severe resorption process.

Discussion

An accurate identification process of the mental foramen was essential both for diagnostic and surgical processes [8]. The mental foramen was part of the mentalis canal, which is consist of mental nerve, sensory innervation of the lower lips, bilateral vestibulum and mesial gingiva of the mandible molar [9]. The position of the mental foramen both horizontally and vertically was reported influenced by many factors. Failure that ocured during the injection and surgery process was usually caused by differences of mental foramen positions in some community groups [8].

Based on previous research it was showed that the most common mental foramen position was found in position B, located at a distance of 1.0 cm -1.5 cm from the lower border of the mandible [10]. The mean of distance from the mental foramen to the inferior border of the mandible in Caucasian population was in the range of 14-15 mm and 10.39-13.67 mm. This is in contrast to the results obtained in the Iranian population who found that the mental foramen was closer to the alveolar crest than the Caucasian population [11].

Many variations of mental foramen's position were influenced by ethnicity, race, sex and age. Furthermore, it was known that mental foramen's position was indeed always moving as each individual grows older whether in term of horizontal or vertical position [9].

In the childhood age, before the deciduous teeth erupted until the position becomes permanent halfway to mandible and closer to the lower border of mandible after all teeth erupted. For the individuals in their old age, resorption occurred in mandible bone would bring mental foramen closer to alveolar ridge. When all teeth have already fallen off (edentulous), mental foramen would appear quite close to alveolar ridge, even in the quite severe resorption state, which caused mental foramen gone and replaced with concave which located in every surface of mandible [12-15].

In geriatric, the position of the foramen mentale moved to the superior border of the mandible. The main cause was tooth loss and resorption of bone. There was a significant difference from the variation of foramen mentale position by age [16]. In menopausal women, estrogen hormone deficiency accelerated skeletal bone loss and alveolar bone resorption. This can be seen from bone mineral density based on orthopantomography examination [17].

Based on that theory, it was similar with the result from this study where the vertical position of mental foramen will always be moving as each individual grows older, and it makes age prediction is possible to be done with the vertical position of mental foramen examination by using panoramic radiography image result. Panoramic radiography was used in this study because the foramen mental would appear consistently than periapical radiography [18-20]. A common limitation of periapical radiography results in detecting the location of the mental foramen was the mental foramen position that appears at the edges of the film made it difficult to accurately measure the position of the mental foramen [21-23].

Conclusion

Mental foramen was the anatomic structure, which located in mandible; this channel becomes the outlet of nervous mental and blood vessel. Mental foramen had many varieties of size, shape and location. This study focused on discussion about the vertical position of mental foramen. Vertically, mental foramen's position was divided into three positions namely lead closer to alveolar ridge, located in the middle of mandible corpus and located closer in lower border of mandible corpus.

Individual's age affected the mental foramen's position. In the eruption period of permanent tooth, mental foramen located closer with alveolar ridge. After passing the eruption period, mental foramen would move to the halfway of mandible corpus lower border. As each individual's grow

older and teeth had fallen off, mental foramen would appear again getting closer with alveolar ridge, it was related with the process of alveolar bone resorption that already occurred.

The process of identifying mental foramen to predict individual's age in the relation with forensic odontology was possible to be done by using roentgen image in mandible of the dead victim. Although it still required further identification, mental foramen's position could be one of the references in predicting individual's age.

References

1. Nayak S, George R, Shenoy A, Sundharam S. Age estimation in forensic dentistry. *Int J Sci Res* 2014; 3:333-8.
2. Budhiraja V, Rastogi R, Lalwani R, Goel P, Bose SC. Study of position, shape and size of mental foramen utilizing various parameters in dry adult human mandibles from north India. *ISRN Anatomy* 2013; Article ID 961429. doi: 10.5402/2013/961429.
3. Al-Juboori MJ, Hua CM, Yuen KY. The importance of the mental foramen location detection by using different radiographic technique: Mini review. *Int J Med Imag* 2014; 2(3):63-8. doi: 10.11648/j.ijmi.20140203.14.
4. Rupesh S, Winnier JJ, John SA, Joy T, Rao AP, Reddy V. Radiographic study of the location of mental foramen in a randomly selected Asian-Indian population on digital panoramic radiographs. *J Med Sci* 2011; 11(2):90-5. doi: 10.3923/jms.2011.90.95.
5. Singh R, Srivastav AK. Evaluation of position, shape, size and incidence of mental foramen and accessory mental foramen Indian adult human skulls. *Anatomy* 2010; 5:23-9. doi: 10.2399/ana.10.004.
6. Al-Juboori M, Al-Wakeel H, Yun C, Wen F. Location of mental foramen among malaysia populations: retrospective study by using orthopantomogram. *World J Med Med Sci Res* 2013; 1(5):85-90.
7. Kojiku L, Weiglein A, Kamberi B, Hoxha V, Meqa K, Städler P. Position of the mental foramen in Kosovar population. *Coll Antropol* 2013; 37(2):545-9.
8. Parnami P, Gupta D, Arora V, Bhalla S, Kumar A, Malik R. Assessment of the horizontal and vertical position of mental foramen in Indian population in terms of age and sex in dentate subjects by panoramic radiographs: A retrospective study with review of literature. *Open Dent J* 2015; 9:297-302. doi: 10.2174/1874210601509010297.
9. Aher V, Pillai P, Ali FM, Mustafa M, Ahire M, Mudhol A, Kadri M. Anatomical position of mental foramen: A review. *Global J Med Public Health* 2012; 1(1):61-64.
10. Chowdhury TG, Rahman D, Jannat TA, Hossain M, Sultana A, Iqbal A, Noor AE. Radiographic position of mental foramen in selected urban population of Bangladesh. *Update Dent Coll J* 2015; 5(1):3-9.
11. Shekhi M, Kheir MK. CBCT assesment of mental foramen position relative to anatomical landmarks. *Int J Dent* 2016; Article ID 5821048. doi: 10.1155/2016/5821048.
12. Gupta S, Somi JS. Study of anatomical variations and incidence of mental foramen and accessory mental foramen in dry human mandibles. *Nat J Med Res* 2012; 2(1):28-30.
13. Ajmal M. Evaluation of mental foramen position from panoramic dental radiographs. *J Contemp Dent Pract* 2014; 15(4):399-402.
14. Swamy N, Nagaraj T, Ghose N, Jagadish C, Sreelakshmi N, Goswami R. Radiograph study of mental foramen type and position in Bangalore Population. *J Med Radiol Pathol Surg* 2015; 1:5-8.
15. Achmad H, Ramadhany YF. Effectiveness of chitosan tooth paste from white shrimp (*Litopenaeus vannamei*) to reduce number of streptococcus mutans in the case of early childhood caries. *J Int Dent Med Res* 2017; 10(2):358-63.
16. Achmad H, Supriatno, Singgih MF, Hendrastuti H. Akt signal transduction pathways and nuclear factor-kappa B (NF- κ B) transcription as a molecular target of oral tongue squamous cell carcinoma (SP-C1) using papua's anhill plant (*Myrmecodia pendans*). *Pak J Biol Sci* 2016; 19(8-9):323-30. doi: 10.3923/pjbs.2016.323.330.
17. Achmad MH, Adam M, Oktawati S, Karim SR, Thahir H, Pratiwi R et al. An overjet reduction of class II, division 1 malocclusion in twin block dentofacial orthopedic and fixed orthodontic treatment: Case report. *J Int Dent Med Res* 2017; 10(3):1010-16.

18. Achmad H, Khairunnisa P, Mardiana, Auliya AZK. Potentially of extracted papua's anthill (*myrmecodia pendans*) as antitumor to emphasis the expression of vascular endothelial growth factor cell burkitt's lymphoma cancer. *Asian J Microbiol Biotechnol Environm Sci* 2018; 20(1):108-12.
19. Achmad, H. et al. 2018. Apoptosis induction (Caspase-3,-9) and human tongue squamous cell carcinoma VEGF angiogenesis inhibition using flavonoid's ethyl acetate fraction of papua ant hill (*Myrmecodia pendans*) SP-C1. *J Int Dent Med Res* 2018; 11(1):276-84.
20. Achmad H, Hendra CM, Sri H, Imam S, Muliaty Y, Rahmah KR, Putri K. Prevalence of medically compromised children regarding dental caries and treatment needs in Wahidin Sudirohusolo hospital. *J Int Dent Med Res* 2017; 10(3):915-20.
21. Achmad H, Tahir H, Adam M, Ramadhany YF. Increased overjet in growing child, problem solving in pediatric dentistry. *J Int Dent Med Res* 2017; 10(2):374-9.
22. Achmad H, Rasmidar S, Hendrastuti H, Sri H, Hasanuddin T, Mardiana A, Susilowati, Ramadhany YF. Biopsychosocial identification of early childhood caries (ECC) as a predictor of risk factors of caries in pre-school children. *J Int Dent Med Res* 2018; 11(1):107-15.
23. Adam AM, Achmad MH, Fahrudin AM. Efficacy of mouthwash from Aloe vera Juice after scaling treatment on patient with gingivitis: A clinical study. *Pesq Bras Odontoped Clin Integr* 2018; 18(1):e3959. doi: 10.4034/PBOCL.2018.181.32.

Characteristics Vertical Position of Mental Foramen Reviewed by Panoramic Radiography as a Guide in Predicting Individual's Age on Forensic Odontology Examination

ORIGINALITY REPORT

%22
SIMILARITY INDEX

%16
INTERNET SOURCES

%12
PUBLICATIONS

%14
STUDENT PAPERS

PRIMARY SOURCES

1	revista.uepb.edu.br Internet Source	%8
2	Submitted to Universitas Indonesia Student Paper	%3
3	Submitted to Universiti Sains Malaysia Student Paper	%2
4	www.sleepclinic.be Internet Source	%1
5	Nikos Makris. "Evaluation of the visibility and the course of the mandibular incisive canal and the lingual foramen using cone-beam computed tomography : Evaluation of the visibility and course of the mandibular incisive canal", Clinical Oral Implants Research, 04/19/2010 Publication	%1
6	actascientific.com Internet Source	%1

7 "Free Communication Sessions 01-20 and Poster Sessions 01-16", International Dental Journal, 2015. %1
Publication

8 Alessandro Leite Cavalcanti, Taynná Dantas de Arruda, Liege Helena Freitas Fernandes, Jeime Iara Bezerra de Freitas Leal et al. "Use of Medicines by Infants with Microcephaly Caused by Congenital Zika Virus Infection and Implications to Oral Health", Pesquisa Brasileira em Odontopediatria e Clínica Integrada, 2020 %1
Publication

9 Mahnaz Sheikhi, Mitra Karbasi Kheir. "CBCT Assessment of Mental Foramen Position Relative to Anatomical Landmarks", International Journal of Dentistry, 2016 %1
Publication

10 Submitted to Pacific University %1
Student Paper

11 www.epsilon.insee.fr %1
Internet Source

12 Ario Santini, Moira Land. "A Comparison of the Position of the Mental Foramen in Chinese and British Mandibles", Cells Tissues Organs, 1990 <%1
Publication

13 ama.ba

Internet Source

<% 1

14

www.ejomr.org

Internet Source

<% 1

15

www.peertechz.com

Internet Source

<% 1

16

Submitted to University of Babylon

Student Paper

<% 1

17

www.revodontolunesp.com.br

Internet Source

<% 1

18

Thomas von Arx, Scott Lozanoff. "Clinical Oral Anatomy", Springer Science and Business Media LLC, 2017

Publication

<% 1

19

www.jrmds.in

Internet Source

<% 1

20

www.birpublications.org

Internet Source

<% 1

21

Priyanka Parnami, Deepak Gupta, Vishal Arora, Saurabh Bhalla, Adarsh Kumar, Rashi Malik. "Assessment of the Horizontal and Vertical Position of Mental Foramen in Indian Population in Terms of Age and Sex in Dentate Subjects by Pano-ramic Radiographs: A Retrospective Study with Review of Literature", The Open

<% 1

22 M. L. Walters, K. Dautenhahn, S. N. Woods, K. L. Koay, R. Te Boekhorst, D. Lee. "Exploratory studies on social spaces between humans and a mechanical-looking robot", Connection Science, 2006 <% 1

Publication

23 Jaju , Prashant P. | Garcha , Vikram | Jaju , Sushma P.. "Accessory Mental Foramina Detection by Cone Beam Ct in Indian Population \\ Smile Dental Journal .- 2013 , Vol. 8 , No. 3 , pp. 32 - 37.", MENA Co. for Dental Services, 2013. <% 1

Publication

24 S. Rupesh, J. Jasmin Winnier, Sherin Anna John, Tatu Joy, Arun Prasad Rao, Venugopal Reddy. "Radiographic Study of the Location of Mental Foramen in a Randomly Selected Asian Indian Population on Digital Panoramic Radiographs", Journal of Medical Sciences(Faisalabad), 2011 <% 1

Publication

25 Submitted to MAHSA University <% 1

Student Paper
