

Review Article

Periodontal considerations for denture placement: A literature review

ARNI IRAWATY DJAIS¹, SRI OKTAWATI¹, HARUN ACHMAD^{2*}, ERI HENDRA JUBHARI³, SHINTA RAHMA M.⁴, FIRMAN SALAM⁴, NUR MASYTA S.⁴, DANIEL TETAN-EL⁴

¹Lecturer of Periodontology Department, Faculty of Dentistry, Hasanuddin University, Indonesia

²Lecturer of Pediatric Dentistry Department, Faculty of Dentistry, Hasanuddin University, Indonesia

³Lecturer of Prosthodontic Department, Faculty of Dentistry, Hasanuddin University, Indonesia

⁴Periodontology Specialist Educational Program of Dentistry Faculty, Hasanuddin University, Indonesia

*Corresponding Author

Email ID: harunachmader@gmail.com

Received: 11.10.20, Revised: 12.11.20, Accepted: 11.12.20

ABSTRACT

A healthy periodontal structure such as adequate alveolar bone and healthy gingiva should be considered prior to denture placement. The success of using dentures is greatly supported by the health of the periodontal tissues. Periodontal preparation for denture placement is carried out in two stages, including the first stage is the form of periodontal inflammation control with a non-surgical and surgical approach which includes emergency treatment, tooth extraction with poor prognosis, oral hygiene instructions, scaling and root planning, periodontal surgery, and additional orthodontic treatment if needed and the second stage of pre-prosthetic periodontal surgery includes management of mucogingival defects, maintenance of ridge morphology after tooth extraction, crown lengthening procedures, and reconstruction of alveolar ridges. In addition, periodontal maintenance after denture placement should also be considered for the long-term success of the denture prognosis.

Keywords: Periodontal Disease, Dental Prosthesis, Pre-Prosthetic Surgery, Oral Hygiene.

INTRODUCTION

Healthy periodontal tissue should be considered before undergoing prosthodontic treatment, for example in the making of dentures. The success of using dentures is greatly supported by the health of the periodontal tissues. Some of the things that are taken into consideration including the condition of the remaining teeth, the quality and quantity of periodontal tissue, periodontal topography, traumatic occlusion, tooth mobility, preprosthetic surgical treatment, masticatory function, and aesthetics.¹

The denture enhances chewing ability, provides support for facial muscles, and improves facial appearance and smile.² Some things that must be considered in dentures are that they do not cause periodontal tissue damage, such as disturbing oral hygiene due to the presence of dentures with rough surfaces, uneven occlusal pressure, and restoration edges or poor contact points and tooth contours.^{3,4}

This review will discuss the periodontal considerations for supporting the success of dentures before insertion and during use.

LITERATURE REVIEW

Etiology of Periodontal Abnormalities Associated with Dentures: Placement of removable partial dentures (RPDs) can affect the

ecology in the oral cavity due to increased plaque accumulation in the remaining teeth.⁵ Plaque accumulation can also be caused by subgingival restoration in the cervical region. Plaque tends to develop apically and causes periodontal destruction and tooth loss.⁶ Improper placement of the subgingival margins can stimulate the formation of organic structures in the restoration margin area and result in a non-tight or rough restoration margins that can complicate plaque control and long-term periodontal health care as well as expansion of the restoration to the "biological width" area.^{7,8} Temporary restoration of inadequate crown placement is also known to cause inflammation of the marginal area and migration of the junctional epithelium apically.^{4,9} Clinical studies have shown that the periodontal condition of the abutment teeth can be related to the design of the denture.¹⁰ The mobility of the abutment tooth can be influenced by several factors including the location of the rest, contour and stiffness of the connector, and expansion of the denture.⁵ Improper clasp design can also cause damage to the denture abutment teeth due to excessive stress leading to occlusal trauma.¹⁰ Excessive contour restoration can inhibit plaque control in the gingival margin area and thus may affect periodontal health.¹¹

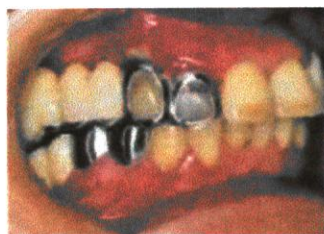


Fig.1:Wrong contour design and overhanging margins of the metal skeleton dentures accompanied by poor oral hygiene lead to chronic periodontitis.¹¹

Periodontal Preparation for Denture Fitting

Periodontal screening of patients who will use dentures is no different from patients requiring other types of prosthetic treatment. Periodontal assessments that should be assessed include oral hygiene, presence of plaque and gingival inflammation, attachment loss, remaining bone support, and tooth mobility. The aim of this phase is to diagnose periodontal conditions that could compromise the long-term prognosis.¹²

In general, the preparation of the periodontium for denture placement can be divided into two stages, including :

1. Control of periodontal inflammation with a non-surgical and surgical approach, which includes emergency care, tooth extraction with poor prognosis, oral hygiene instructions, scaling and root planning, periodontal surgery, and additional orthodontic treatment if needed.
2. Preprosthetic periodontal surgery, in the form of handling mucogingival defects, maintenance of ridge morphology after tooth extraction, crown lengthening procedures, and reconstruction of alveolar ridges.⁵

Other periodontal preparations such as tooth extraction can be carried out before definitive periodontal therapy is administered.¹³ The aim of definitive periodontal treatment is to eliminate periodontal disease, treat any defects that may hinder plaque control, and create a better environment for cleaning.¹² Elimination of exostosis, torus, hyperplastic tissue, muscle adhesions, and frenulum, can be performed using periodontal surgical techniques. The health of the remaining periodontal tissues of the teeth, especially those to be used as supports, should be carefully evaluated by the dentist and corrective steps taken before the denture is made.¹³

Pre-Prosthetic Periodontal Surgery

Pre-prosthetic surgery is defined as a periodontal surgical procedure designed to facilitate the manufacture of a prosthesis or to improve the prognosis of prosthodontic treatment. Pre-prosthetic surgery aims to remove certain lesions or abnormalities in the hard and soft tissues of the jaw so that the placement of the prosthetic

device can be successful.¹⁴ Some pre-prosthetic periodontal surgeries that are often performed before denture are made, namely surgical procedures for mucogingival repair or mucogingival surgery, alveolar ridge preservation procedure after tooth extraction, crown lengthening procedure, and alveolar bone reconstruction.⁴

a. Mucogingival Surgery

Mucogingival surgery is defined as a periodontal plastic surgery procedure designed to correct defects in the morphology, position, and/or number of gingiva surrounding the teeth.¹⁵ Mucogingival surgical procedures are divided into several categories, namely free soft tissue graft, soft tissue pedicle graft, free soft combination tissue and soft tissue pedicle graft, frenectomy and reconstruction of the gingival papilla.⁴ These surgical procedures are often indicated prior to prosthetic restoration treatment. Restorative treatment was performed at least two months after mucogingival surgery.⁵

b. Alveolar Ridge Preservation

Ridge preservation is a procedure performed during or after extraction designed to minimize external resorption of the alveolar ridge and maximize bone formation in the socket.¹⁶ The Alveolar Ridge Preservation (ARP) procedure aims to maintain an aesthetic contour of the alveolar ridge, prevent alveolar ridge atrophy, and maintain adequate bone dimensions for the placement of prosthetic or pontic implants to be used in bridge denture restorations.^{3,17}

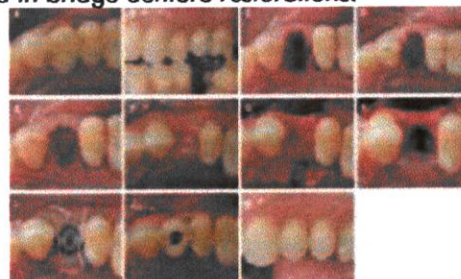


Fig.2: (A, B) Tooth 24 mesiodistal fracture. (C) Appearance after tooth extraction (D) Application of demineralized bovine bone matrix with collagen (E) A collagen matrix with a diameter of 8 mm is sutured to the gingival margin of the host. (F) Six months after healing. (G, H) Implant placement without further augmentation (I) transmucosal healing. (J, K) Clinical features 6 weeks later, it appears that the ceramic crown has been attached.¹⁷

c. Crown Lengthening

Crown lengthening is a periodontal resection procedure by removing part of the periodontal supporting tissue to increase the opening of the clinical dental crown. This procedure is aimed at

maintaining a biological width in relation to the health of the periodontal tissue, providing sufficient retention and resistance to the restoration to be performed, more accurate impression procedure, placing the restoration margins, and adjusting the gingival level for esthetic needs.^{18,19}

Some conditions requiring crown lengthening include teeth with sub-gingival caries or short teeth with extensive caries, fractured teeth, and short clinical crowns with or without esthetic disturbances.²⁰ Several surgical techniques can be used in crown lengthening procedures, namely gingivectomy, Apically Positioned Flap (APF), and APF with bone reduction (osteoplasty / ostectomy).²¹

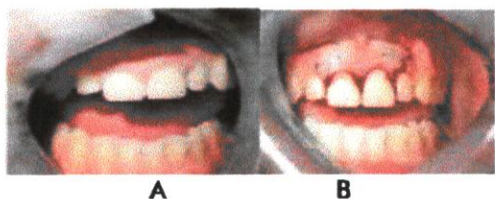


Fig.3: A) The central incisor was restored with jacket crown resulting from trauma in childhood. This expansion in the biological width area causes gingivitis around the tooth due to poor oral hygiene control. The gingival margins of the central incisors were seen to be significantly more coronal than the adjacent lateral incisors. B) APF is designed to widen the margins of the restoration and create gingival harmonization that matches the adjacent lateral incisors. Look for sutures in the labial groove area. This serves to shorten the flap and maintain apical tension during the healing process. 17

d. Alveolar Bone Reconstruction

Alveolar defects can cause several aesthetic and functional problems. Aesthetic problems such as the loss of the papilla which causes the opening of the interdental space, loss of buccal contours, and the texture of the gingiva becomes less aesthetic. Functional problems can include phonetic disorders and food impaction under the pontic. As an understanding of the biomechanical requirements for long-term prosthetic resistance and the increasing use of implants in aesthetic restoration, ridge reconstruction prior to implant placement has become a necessary procedure for a number of edentulous patients.²²

For the case of aesthetic pontic construction, small alveolar defects can be treated with soft tissue ridge augmentation, while larger alveolar defects or in the area that will receive the implant use hard tissue ridge augmentation.³

Periodontal Maintenance after Denture Placement

Periodontal maintenance was performed after definitive periodontal therapy was performed and continued at varying time intervals based on dentition condition or implant placement. This procedure aims to :

1. To minimize recurrence and progression of periodontal disease in patients previously treated for gingivitis and periodontitis.
2. To reduce the incidence of tooth loss with how to monitor the teeth and all prosthetic devices on natural teeth.
3. To increase the likelihood of finding and treating diseases or other conditions in the oral cavity.²³

When a dentist places a removable partial denture, it is necessary to instruct the patient on the proper use, such as the importance of removing the denture at least 6-8 hours per day and stored in a dry environment. Patients wearing dentures must continue to exercise regular control and not only in the event of discomfort associated with the use of dentures or emergency events such as broken or fractured dentures.²¹ An important aspect that must be considered when carrying out control is how the patient's prosthetic condition is. The denture that does not fit properly or malocclusion can change the function of the denture causing undesirable stress and pressure on the remaining tooth and soft tissue.¹²

DISCUSSION

Understanding the identification of the etiological factors that cause periodontal disease can help assess the long-term or short-term prognosis of the status of the teeth.²⁴ A prosthesis is said to be successful if the supporting teeth and periodontium tissue are in healthy condition. An improperly made prosthesis can lead to food retention and plaque buildup, which in turn leads to the development of periodontal disease. Periodontal disease will lead to loss of attachment, tooth mobility, and ultimately tooth loss.²³

In fixed dentures, it is very important to assess the abutment tooth from a periodontal perspective for long and short term treatment planning. Tooth mobility, furcation involvement, severity of bone loss, bleeding / exudation from the gingival pocket are some of the periodontal factors that need to be checked before finalizing the prosthetic treatment plan. The periodontal health of the abutments is very important before proceeding with further treatment. Likewise, it should be remembered that the final restoration/prosthesis to be cemented must be carefully planned and must align with the

periodontium. The most important factor to consider is the invasion of the biological width by the restoration margins created. This can lead to gingival inflammation, loss of connective tissue adhesions, and bone loss.²³

Apart from control of inflammation, pre-prosthetic periodontal surgery can assist in the management of soft and hard tissue required for successful denture placement.^{24,25,26,27} All dentures requiring hard and soft tissue support should be evaluated with extreme caution prior to denture fabrication. At the very least, anatomically corrected surgical procedures should be considered in every patient who is planning to use a conventional prosthesis.^{12,28,29,30}

Pre-prosthetic surgery is basically the surgical preparation of either total edentulous or partially edentulous before the denture fabrication. This procedure has evolved from being merely a correction of irregular shapes, exostoses, and simple dentoalveolar hyperplastic tissue, to now include various vestibular deepening procedures as well as inlay and onlay augmentation surgeries which are prerequisites for successful implant restoration. The surgical procedure used may differ depending on the problems encountered in each patient, but the aim of this procedure is to eliminate disease, preserve the oral tissue structure, and provide remaining tissue support to the masticatory, functional, and aesthetic pressure of the denture.²⁵

Regular periodontal maintenance is the key to reducing the incidence of tooth loss or implant failure after denture placement. Adherence to regular periodontal maintenance controls can prevent recurrence of periodontal disease and to maintain the integrity of treatment outcomes.⁶

CONCLUSION

From the foregoing description, it can be concluded that the periodontal preparation prior to denture preparation, including control of existing periodontal diseases as well as preprosthetic periodontal surgery was performed if necessary and adjusted according to the indications. The success of using dentures is greatly supported by the health of the periodontal tissues. Therefore, it is necessary to pay attention to the factors that influence before and during the use of dentures, especially on hygiene and damage to the periodontal tissue.

REFERENCES

1. Abduo J, Lyons KM. Interdisciplinary interface between fixed prosthodontics and periodontics. *Periodontol* 2000.2017; 74 (1): 40–62.
2. Wahyuni S, Mandanie SA. Making Combination Prosthesis with Castable Extracoronal

- Attachment (Laboratory Procedure). *J of Vocational Health Studies*. 2017; 1 (2): 75-81.
3. Philip R. Melnick HHT. Preparation of the Periodontium for Restorative Dentistry. In: Newman and Carranza's Clinical Periodontology. 13th ed. Philadelphia: Elsevier Inc.; 2019. p. 696–713.
4. Masulili SLC, Kemal Y, Masulili C. Periodontal preparation in denture making. *J Dentomaxillofacial Sci*. 2013; 12 (2): 129.
5. Lavanya E, Ganapathy D, Sheeba S. Effect of removable partial denture on periodontal health of abutments. *Res J Pharm Technol*. 2018; 11 (6): 2587–90.
6. Preetika Bansal, Pardeep Bansal T. Interrelationship Between Prosthodontics and Periodontics-A Review Article. *J Appl Dent Med Sci*. 2018; 4 (1): 24–8.
7. Madalina Nicoleta Matei, Constanta Mocanu KE. Periodontal consideration's in fixed prosthodontics. *Rom J Oral Rehabil*. 2014; 6 (1): 96–100.
8. Paniz G, Nart J, Gobbato L, Mazzocco F, Stellini E, De Simone G, et al. Clinical Periodontal Response to Anterior All-Ceramic Crowns with Either Chamfer or Feather-edge Subgingival Tooth Preparations: Six-Month Results and Patient Perception. *Int J Periodontics Restorative Dent*. 2017; 37 (1): 61–8.
9. Shenoy VK, Rodrigues S. Iatrogenic dentistry and the periodontium. *J Indian Prosthodont Soc*. 2007; 7 (1): 17–20.
10. Chaiyabutr Y, Brudvik JS. Removable partial denture design using milled abutment surfaces and minimal soft tissue coverage for periodontally compromised teeth: A clinical report. *J Prosthet Dent*. 2008; 99 (4): 263–6.
11. Corbet E, Smales R. Oral diagnosis and treatment planning: Part 6. Preventive and treatment planning for periodontal disease. *Br Dent J*. 2012; 213 (6): 277–84.
12. Petridis H, Hempton TJ. Periodontal Considerations in Removable Partial Denture Treatment: A Review of The Literature. *Int J Prosthodont*. 2001; 14 (2): 164–72.
13. Carr AB, Brown DT. Preparation of the Mouth for Removable Partial Dentures. *McCracken's Removable Partial Prosthodont*. 2011; 185–204.
14. Chari H, Shaik K. Preprosthetic Surgery: Review of Literature. *IJSS Case Report* 2016; 3 (4): 419–24.
15. Dym H, Tagliareni JM. Surgical Management of Cosmetic Mucogingival Defects. *Dent Clin North Am*. 2012; 56 (1): 267–79.
16. Darby I, Chen S, De Poi R. Ridge preservation: What is it and when should it be considered. *Aust Dent J*. 2008; 53 (1): 11–21.
17. Horváth A, Mardas N, Mezzomo LA, Needleman IG, Donos N. Alveolar ridge preservation. A systematic review. *Clin Oral*

- Investig. 2013; 17 (2): 341–63.
18. Fauziah Karimah H. Crown Lengthening Treatment for Anterior Teeth Post Fracture. *Dent J incisors* 2018; 7 (2): 58–62.
 19. Aristiyanto R, Ratih DN. Functional Crown Lengthening: Biological Width Correction. *J Indones Dent Assoc.* 2020; 3 (1): 43.
 20. Geoffrey Bateman, Shuva Sava ILCC. *Contemporary Periodontal Surgery: An Illustrated Guide to Art Behind The Science.* London: Quintessence Publishing Co.Lt; 2007
 21. Kalsi HJ, Bomfim DI, Hussain Z, Rodriguez JM, Darbar U. Crown Lengthening surgery: An overview. *Prim Dent J.* 2020; 8 (4): 48–53.
 22. Achmad H, Djais AJ, Petrenko EG, Larisa V, Putra AP. 3-d printing as a tool for applying biotechnologies in modern medicine. *International Journal of Pharmaceutical Research*, 2020. 12(4), pp. 3454-3463.
 23. Achmad H, Djais AI, Jannah M, Huldani, Putra AP. Antibacterial chitosan of milkfish scales (*Chanos chanos*) on bacteria *porphyromonas gingivalis* and *agregatibacter actinomycetescommitans*. *Systematic Reviewa In Pharmacy*, 2020. 11(6), pp. 836-841.
 24. Achmad H, Djais AI, Syahrir S, Fitri A, Ramadhany YF. A literature us regarding the use of herbal medicines in pediatric dentistry. *International Journal of Pharmaceutical Research.* 2020. 12,PP. 881-897.
 25. Achmad H, Djais AI, Syahrir S, Fitria A, Ramadhany YF. Impact Covid-19 in pediatric dentistry: A literature review. *International Journal of Pharmaceutical Research*, 2020. 12,p.830-840.
 26. Amrullah SSA, Sani R, Arifin N, Ruslin M. Alveolar bone augmentation with distraction osteogenesis Alveolar ridge augmentation using distraction osteogenesis. *J Dentomaxillofacial Sci.* 2012; 11 (3): 174.
 27. Supplement. Parameters on Periodontal Maintenance. *J Periodontol.* 2000; 71 (5-s): 849–50.
 28. Rajanna S, Lakshmaiahenkatesh P, Suryaprakash M, Varadan K. Pre prosthetic reconstruction of alveolar ridge. *J Int Clin Dent Res Organ.* 2011; 3 (2): 78.
 29. Bhuskute M, K Shet R. Preprosthetic surgery: An adjunct to complete denture therapy. *J Int Clin Dent Res Organ.* 2019; 11 (1): 49.
 30. Achmad H, Thahir H, Rieuwpassa I, Mardiana AA, Oktawati S, Samad R, Djais AI, Gani A, Singgih MF, Madjid F, Admy SC. The Effectiveness of *Channa striata* Extract Antimicrobial Effect on Periopathogen Bacteria (*Porphyromonas gingivalis* and *Aggregatibacter actinomycetemcomitans*). *Systematic Reviews in Pharmacy.* 2020; 11(4): 319-323. doi: 10.31838/srp.2020.4.46
 31. Achmad H., Huldani, Carmelita A.B., Fauziah, Hidayah N., Bokov D. Antioxidant and antiviral potential of brown algae (*Phaeophyceae*). *International Journal of Pharmaceutical Research.* 2020; 3(12): 2117-2125. DOI: 10.31838/ijpr/2020.12.03.292 <http://www.ijpronline.com/ViewArticleDetail.aspx?ID=17012> <http://www.scopus.com/inward/record.url?eid=2-s2.0-85089415736&partnerID=MN8TOARS>
 32. Sukmana B.I., Edyson, Thahir H., Achmad H., Huldani, Bokov D.O. Research review on secondary metabolite compounds of *Mangifera casturi* bark and their functions. *International Journal of Pharmaceutical Research.* 2020; 3(12): 2155-2161. DOI: 10.31838/ijpr/2020.12.03.309 <http://www.ijpronline.com/ViewArticleDetail.aspx?ID=17079> <http://www.scopus.com/inward/record.url?eid=2-s2.0-85089431331&partnerID=MN8TOARS>
 33. Achmad H., Sarina, Bokov D.O., Ramadhany Y.F., Kirichenko E.V., Markov A. The Impact of Using Antibiotic Drugs in Pediatric Dentistry. *International Journal of Pharmaceutical Research.* 2020; 4(12): 2901-2910. DOI: 10.31838/ijpr/2020.12.04.400 <http://www.scopus.com/inward/record.url?eid=2-s2.0-85095790474&partnerID=fpDjhFsn> <http://www.ijpronline.com/ViewArticleDetail.aspx?ID=18024>