Book of Abstract

1st International Conference of Biophysical Technology in Dentistry (ICoBTD 2018)

in conjuction with

10th International Scientific Meeting in Dentistry (TIIKG 10)

Editors

drg. M. Ruslin, M.Kes., Sp.BM(K)
drg. Acing Habibie, Ph.D
drg. Fuad Husain Akbar, M.Kes., Ph.D
drg. M.Ikbal, Sp.Pros
drg. A. St. Hajrah Yusuf

Layouters

Asyraf Afif Alfian
Moefida Ahmad

UHPress
UPT Unhas Press

Book of Abstract

1st International Conference of Biophysical Technology in Dentistry
(ICoBTD 2018)

in conjuction with

10th International Scientific Meeting in Dentistry (TIIKG 10)

Editors

drg. M. Ruslin, M.Kes., Sp.BM(K)
drg. Acing Habibie, Ph.D
drg. Fuad Husain Akbar, M.Kes., Ph.D
drg. M.Ikbal, Sp.Pros
drg. A. St. Hajrah Yusuf

Layouters
Asyraf Afif Alfian
Moefida Ahmad

Publisher:

UHPress
UPT Unhas Press

Book of Abstract

1st International Conference of Biophysical Technology in Dentistry (ICoBTD 2018)

in conjuction with
10th International Scientific Meeting in Dentistry (TIIKG 10)

Editors
drg. M. Ruslin, M.Kes., Sp.BM(K)
drg. Acing Habibie, Ph.D
drg. Fuad Husain Akbar, M.Kes., Ph.D
drg. M.Ikbal, Sp.Pros
drg. A. St. Hajrah Yusuf

Layouters
Asyraf Afif Alfian
Moefida Ahmad

ISBN: 978-979-530-181-3

Publisher:
UPT Unhas Press

Kampus Unhas Tamalanrea, Jl. Perintis Kemerdekaan Km. 10
E-mail: unhaspress@gmail.com

Radiography Assessment to Diagnose Case of Oroantral Fistula: A Review

Muliaty Yunus[1], Arni Irawaty Djais[2], Levina Priscilla[1], Dwi Putri Wulansari[1]
1 Dental Radiology Department, Faculty of Dentistry, Hasanuddin University, Makassar, South Sulawesi, Indonesia
2 Periodontology Department, Faculty of Dentistry, Hasanuddin University, Makassar, South Sulawesi, Indonesia

ABSTRACT

Background: Oroantral Fistula is pathological condition such as canal connecting antrum/ maxillary sinus floor to oral cavity. Oroantral Fistula is one of complications that can happen in tooth extraction. Oroantral Fistula usually happens due to extraction of upper posterior teeth such as first premolar, second premolar, first molar and second molar which has incidence about 0,31%-3,8%. To help diagnosing and observing further pathological condition, radiography examination should be done on this case. **Objectives:** By radiography examination, Oroantral Fistula can be easier to be known so that treatment can be done immediately to prevent further complications. **Discussion:** Radiography Examination is like panoramic photo using to observe the relation of teeth and sinus, location of foreign object such as tooth, radix of tooth or bone fragment which is pushed into maxillary sinus during tooth extraction. Computed Tomography Scan or Cone Beam Computed Tomography can show discontinuity of maxillary sinus floor and when acute infection is happening then the liquid can be seen in maxillary sinus. **Conclusion:** Radiography is useful as additional examination that can help diagnosing diseases such as Oroantral Fistula. Type of radiography techniques for this case are Panoramic, Computed Tomography Scan and Cone Beam Computed Tomography.
Key Words: *Oroantral Fistula, Maxillary Sinus, Panoramic, Computed Tomography*

Introduction

Oroantral Fistula is tube which pathologically related antrum/ maxillary sinus floor with oral cavity. Oroantral Fistula is one of complication in tooth extraction. Oroantral Fistula usually happens due to tooth extraction of upper posterior tooth such as second premolar, first molar or second molar which has incidence about 0,31%-3,8%. Besides caused by tooth extraction, Oroantral Fistula can also happen due to iatrogenic trauma, infection, malignant tumor and osteomyelitis.[1-4] Maxillary sinus has a close relation with root of upper second premolar and upper first molar. If infection or other pathological conditions happen such as radicular cyst or periapical granuloma on apex of tooth, it can cause bone resorpstion of maxillary sinus floor. Extraction of upper premolar and molar can lead to Oroantral Fistula so that bacteria from oral cavity is moving on to maxillary sinus and then being maxillary sinusitis.[5]

Etiology and Pathogenesis

Oroantral Fistula can due to some factors: first, extraction of upper posterior teeth such as first molar, second molar and second premolar where their root are so close to antrum.[7] To evaluate the relation between maxillary sinus floor and upper posterior teeth, classification Kwak et alcan be used.[8]

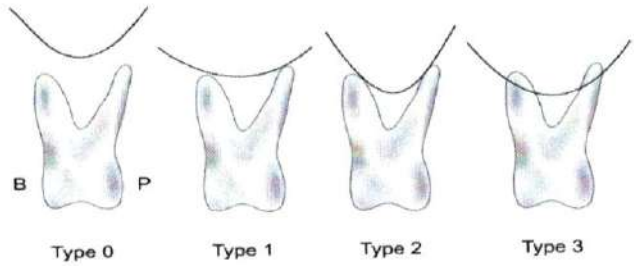

Figure 1 Relation between apex and maxillary sinus floor (Source: Textbook of Oral Surgery)[6]

Second: accident of using instrument such as elevator with excessive pressure in procedure to take fragments or apex of upper posterior tooth, insersion of implant denture and using of curette improperly can cause perforation of epithelium layer from maxillary sinus.[7] Third: shape of antrum floor which curves following contour of root so that bone of antrum wall being thinner. Fourth: pathological tissue on apex of tooth such as radicular cyst, periapical granuloma or neoplasia. Inflamatiom which happens on periapical can cause destruction of bone so that it is going to be fragile. Fifth: enucleation or extraction of big cyst in maxilla and sixth: fracture of big processus alveolaris segment in maxilla.

Characteristics and signs

There is an exposure or hole between oral cavity and antrum. The hole which is formed often undergoing infection, connective tissue or granulation tissue is formed and mucopurulent drainage does exist. At the time of drinking water or gargling, patient will complain of fluid coming out from nose. Oroantral Fistula can also be known with blowing test, patient is instructed to blow with closed nose and opened mouth. When Oroantral Fistula has bappened, puff of air will be heard going through damaged area and in the socket of tooth will be seen air bubble.[9]

Discussion

Radiography examination such as panoramic photo with sinus, location of foreign object like tooth, ro pushed into antrum due to trauma during tooth extr Oliveira et al using panoramic photo to assess Oroa first molar at smoker who have delayed healing. [10]

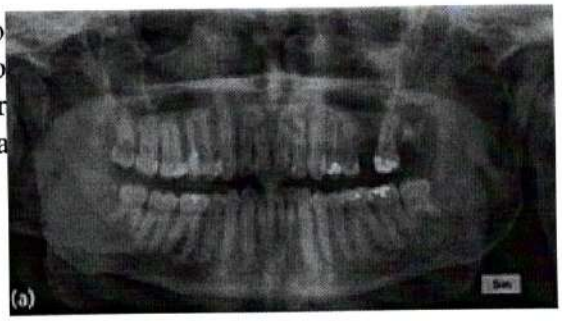

According to Fabrizio Carini et al, diagnose and evaluate case of Oroantral Fistula can be done with CT-Scan/ CBCT examination. In this case report found discontinuity of maxillary sinus floor, there is an opaque canal in

maxillary sinus and focal atrophy of alveolar. Alveolar bone atrophy seems in segment that close to fistula.[11]

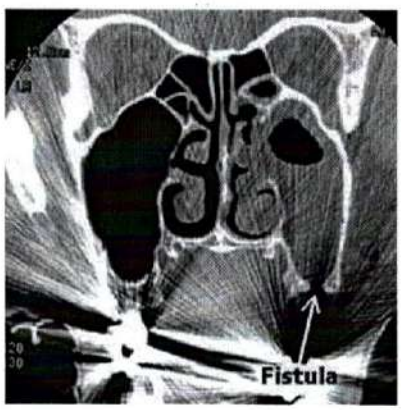

If

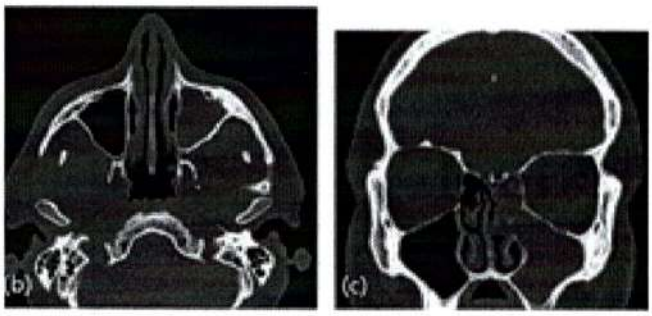

an *Figure 3 Maxillary Sinusitis (Source: (Source: Oral and Maxillofacial Surgery)*[12]

acute sinusitis is happened, it will show increasing of opacity in sinus cavity and chronic sinusitis will show full ossification in sinus cavity indicating that it was fulfilled with hyperplastic tissue, secretory, polyp or both of them.[11]

Conclusion

This paper is aimed to give information about the role of radiography to diagnose disease especially Oroantral Fistula. There are some kinds of radiography examination which can be used to support diagnosing this case such as panoramic examination to observe foreign object going into maxillary sinus through fistula and Computed Tomography examination used to observe fistula condition, maxillary sinus floor and existance of fluid in sinus if infection is happen.

Daftar Pustaka

1. Kamadjaja DB. The role of proper treatment of maxillary sinusitis in the healing of persistent oroantral fistula. Majalah Kedokteran gigi. Dental J. 2008;41:3.
2. Yilmaz T, Suslu AE, Gursel B. Treatment of Oroantral Fistula: Experience With 27 Cases. Am J Otolaryngol.2003;24(4):221-3.
3. Khitab U, Khan A, Tariqkhan M, Alishah AM. Treatment of Oroantral Fistula- a study. Pakistan Oral & Dental J. 2010;30(2):299-302.
4. Ogunsalu C. A new surgical management for oroantral communication. West Indian Med J 2005; 54(4): 261-3
5. Meirelles RC, Mochado R, Pinto N. Oroantral fistula and genian mucosal flap: areview of 25 cases. Rev Bras Otorrinolaringol. 2008;74(1):85-90.
6. Malik NA. Textbook of oral and maxillofacial surgery 3rd edition. Jaypee:Newdelhi;2012. P 637,635,929-930
7. I Wayan Sulastra. Oroantral fistula sebagai salah satu komplikasi pencabutan dan perawatannya. PDGI. 2008 Jan-Apr. 58:7-11

8. Shokri A, Lari S, Youse F, Hashemi L. Assessment of the relationship between the maxillary sinus floor and maxillary posterior teeth roots using cone beam computed tomography. JCDIP. 2014 Okt. 15(5): 619
9. Khandelwal P, Hajira N. Management of Oro-antral Communication and Fistula: Various Surgical Options. World J Plast Surg 2017;6(1):3-8.
10. De Oliveira JCS, De Almeida RS, Faverani LP, Bassi APF, Sonoda CS and Luvizuto ER*.Oro Nasal Communication Closure in Smoker Patient: Case Report. J of Dentistry. 2014; 4(5):1
11. Carini Fabrizio, Longoni Salvatore, Amoso Ernesto, Carini Stefania, Werner Garavello, Gianluca Polcaro. Odontogenic maxillary sinusitis with oro-nasal fistula: a case report. Annali di Stomatologia 2014; 2: 37-39
12. Andersson Lars, Kahnberg Karl, Pogrel Anthony. Oral and maxillofacial surgery. UK: Wiley Blackwell.2010. P.20
13. Gavindrao Anil, Savita Anil. Textbook of oral radiology. New Delhi: Elsevier. 2016. P.713