

# Anti-Arthritic Effect Of Onion Skin Extract On Rat Complete Freund's Adjuvant-Induced

*by* Indah Puspasari

---

**Submission date:** 08-Feb-2023 02:40PM (UTC+0700)

**Submission ID:** 2009190853

**File name:** 1675842025\_Anti-Arthritic\_Effect\_Of\_Onion\_Skin\_Extract\_On\_Rat\_Complete\_Freund\_s\_Adjuvant-Induced.pdf (466.88K)

**Word count:** 3678

**Character count:** 19827

# Anti-Arthritic Effect Of Onion Skin Extract On Rat Complete Freund's Adjuvant-Induced

Ummu Aiman<sup>1</sup> Husnul Khatimah<sup>2</sup> Muhammad Ariiq Saifullah<sup>3</sup> Muhammad Carnegie  
Matondang<sup>4</sup> Dike Dandari Sukmana<sup>5</sup> and Upik Anderiani Miskad<sup>6</sup>

1,2,3 Faculty of Medicine, Hasanuddin University, Makassar, Indonesia

4,5 Faculty of Pharmacy, Hasanuddin University, Makassar, Indonesia

6 Pathology Anatomy Department, Faculty of Medicine, Hasanuddin University, Indonesia

E-mail: <sup>6</sup>upik.miskad@med.unhas.ac.id

10  
**Abstract.** Rheumatoid Arthritis (RA) is a chronic inflammatory disorder and sodium diclofenac as symptomatic management of RA but in long-term used would has gastrohepatology side effect. Previous studies reported onion skin extract has anti-inflammatory effect as an alternative approach in treatment RA symptoms. This study aimed to observe the histological changes in rat's intraarticular joint induced with Complete Freund's Adjuvant (CFA) treated with onion skin extract. The method is an Experimental Study with post-test control group design. Arthritis was induced by intra-articular of Complete Freund Adjuvant (CFA) on the right back knee of rat. Eighteen rats were randomly divided into six groups, first group as a normal control, and five other groups were induced with 100 µg CFA, then these groups were treated differently. One of five group induced as negative control. Three groups were treated orally with onion skin extract in doses 100,200,300 mg/kg body weight and one group treated orally with sodium diclofenac in doses 10 mg/kg body weight as positive control. This study showed that onion skin extract prevents some principal signs of arthritis and significantly reduces the joint damage ( $p=0,00053$ )

## 2 1. INTRODUCTION

Arthritis is a musculoskeletal system disorder that destabilizes normal coupling between degradation and regeneration of articular cartilage in joints following mechanical and a biological collapse in the body [1]. Rheumatoid arthritis (RA) is a chronic autoimmune disease, which leads to swelling of the joints, inflammation of the synovium and destruction of adjacent cartilage and bone [2].

Rheumatoid arthritis is the most common form of autoimmune arthritis, which is affecting more than 1.3 million Americans. Of these, about 75% are women. In fact, 1-3% of women may have rheumatoid arthritis in their lifetime. This disease most often begins between the fourth and sixth decades of life. However, rheumatoid arthritis can start at any age [3]. In Indonesia, the incidence of rheumatoid arthritis is lower than the developed countries like America. The prevalence of rheumatoid arthritis in Indonesia ranges from 0.1% to 0.3% while in the United States reaches 3% [4]. It badly affects in patient's quality of life, work capability, and life expectancy. Besides the consequences on the health status of individuals, RA has a substantial economic impact on patients, their family and society.

Current drug therapies of RA which used non-steroidal anti-inflammatory drugs (NSAIDs) are relatively ineffective at retarding disease progressions [5]. NSAIDs is also caused

significant side effects. The common side effects are nausea, vomit and headache. Sodium diclofenac can relieve the symptoms, but have little beneficial effect on pathology and progression of disease. Patients with the progressing RA require an effective and specific, orally active therapy that will relieve the symptoms and arrest the pathologic progression of disease [6].

Onion in Indonesian is typically used as ingredient in many traditional dishes, but the outer onion peel (skin) is usually wasted. Onions contained rich antioxidants, and is an excellent choice for human daily consumption. Jin et al, showed that the outer layer of the onion peel extract has the highest of quercetin [7]. Quercetin can reduce inflammation and inhibit proinflammatory cytokine such as interleukin-1, IL-6, IL-8 [8]. Therefore, in our study were-investigated the effect of quercetin in the onion skin extract and to prove its anti-arthritis potential.

## 2. MATERIALS AND METHODS

### 2.1 Plant materials

Onion (*Allium cepa*) was collected from Bantaeng and Enrekang, South Sulawesi, in April 2017. In early stage of the onion skin simplicia done the washing process for 30 minute in the running water. After being washed, raw materials dried in the sunlight for 6 hours. Raw materials that have been dried, then going through disortation to get the best raw materials. The drying process at this stage includes two methods, which was direct sunlight drying and the drying process using an vacuum oven. The last drying process using an vacuum oven for 24 hours results 500 mg simplicia then continuously macerated to get the active compound.

### 2.2 Experimental animals

This experimental study used *Rattus norvegicus* as sample. The healthy adult rats weighing approximately 150-250 gram. Total of 18 rats separately placed in a cage made of wire with area size 30 cm x 50 cm x 15 cm. There are six group of the rats. Each cage containing three rats as one group. The animals were provided by the biopharmacy labororium of faculty of pharmacy, Hasanuddin university. They were kept at conventional conditions of humidity, temperature and light. The rat was feeded with ADIII pellets and approved by the Institute Animal Ethics Committee of Medical faculty, Hasanuddin University.

### 2.3 Experimental design

The experimental Rats divided in to 6 group was treated with 100 , 200, and 500 mg/kg body weight of extract and 10 mg/kg body weight of diclofenac sodium as the positive control. Another two group were negative control (only induced by FCA) and normal control. The total experimental animals were 18 rat and they were grouped into 6 groups and each group consist of 3 rat. The six groups of experimental rat were divided as follows:

- Group I : Normal rat
- Group II : Only induced with CFA and sacrificed in day-5 (Negative control)
- Group III : Induced with CFA and treated with oral diclofenac sodium at a daily dose 10 mg/kg body weight
- Group IV: Induced with CFA and treated with oral extract at a daily dose 100 mg/kg body weight
- Group V: Induced with CFA and treated with oral extract at a daily dose 200 mg/kg body weight
- Group VI: Induced with CFA and treated with oral extract at a daily dose 300 mg/kg body weight

#### 2.4. Arthritis Induce by CFA(Complete Freund's Adjuvant)

Every Rats were anesthetized by ether then fixation was conducted at pronation position. CFA was injected through the patellar ligament into the articular space using the femoral condyles as a guide as previous study from Torres-Guzman on 2014.[9] Then, injected , 0.1 mL of CFA by intrarticular injection on the right knee region to induce arthritis. Complete Freund's adjuvant (CFA) has been used to induce inflammation and to study inflammatory pain in several animal models. On the 5th day after induced with CFA, the rats were randomly divided into six groups and treated.

#### 2.5. Extraction Onion Skin

Onion skin were chosen and chopped into small sizes, which then left to dry in the oven with the certain temperature. The 500grams simplicia of onion skin was macerated with 96% ethanol for 5 days. Then, the extract was filtered and evaporated with rotary evaporator to dryness at 40°C and get the 17.1 grams of onion skin extract. The dark brown extract was kept in a desicator and stored at room temperature.

#### 2.6. Phytochemical analysis

The ethanolic extract (100mg) was dissolved in 10 ml of ethanol and used for qualitative phytochemical screening using thin layer chromatography with moving phase methanol and etil acetic (2 : 1) and spectrophotometer UV-Vis. Flavanoid was detected in extract after evapored with amoniac.

#### 2.7. Histopathological preparation

The extract of onion skin with any dozes were started to give at 5th day after CFA induced and given orally for seven days . On 17th day after CFA's induced, the rat was sacrificed at the right knee joint and to fixed the excision of biopsy with formaldehida 40%. Then soaked in alcohols ranging from alcohol 70%, 80%, 96% and 100% in purpose dehydrate water from excision biopsy. After dehydration, the right knee joint of rat clarified using xylo. Then buried in paraffin and cut using a microtome. Furthermore, stained with eosin hematoxylin and then seen through the microscope.

#### 2.8. Histopathological scoring

Histologic sections from the right joints of each animal were examined by graded on a scale of 0–3[8]. Score 0 for no detectable abnormalities. Score 1 for had some inflammatory cell infiltration in the joint space without significant thickened of the membrane of cartilage nor cartilage erosion. Joints with extensive inflammatory cell infiltration and thickened of the cartilage membrane were scored 2. Joints scored as 3 showed significant thickened and fibrosis of the joint capsule, involvement of the articular cartilage, erosion and appearance of inflammatory cells in the joint space.

#### 2.9. Statistical analysis

Data were analyzed SPSS (Statistical Product and Service Solutions) 21. Statistical comparisons were made between d free arthritic rats, normal rats and all other treatment groups. Mann-Whitney U test. p-values less than 0.05 were considered statistically significant.

#### 4.10. Ethical Approval

Animal management protocol followed the guidelines/protocols of Experimental Animal Laboratory, Faculty of Medicine, Hasanuddin University and has received ethical approval from the ethics committee of the health research Medical Faculty of Hasanuddin University (273/H4.8.4.5.31/PP36-KOMETIK/2017).

### 3. RESULT

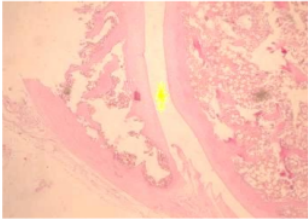
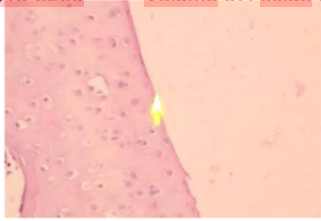
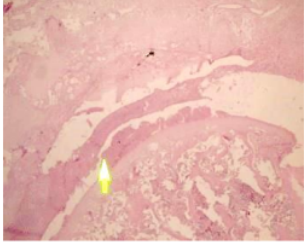
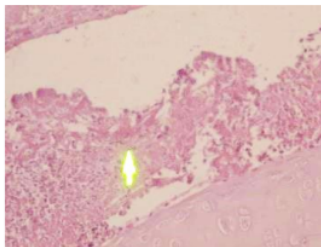
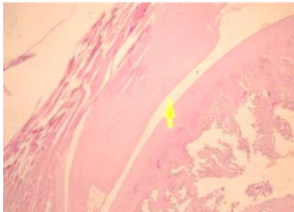
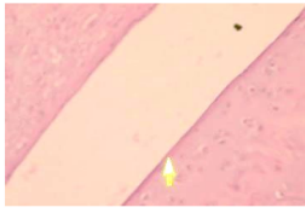
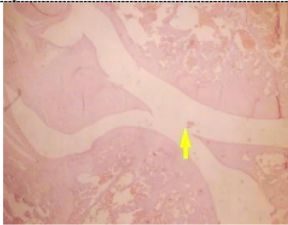
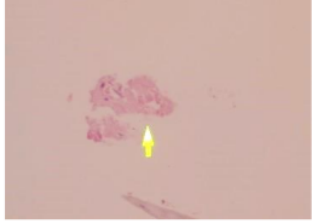
Based on this experiment, 500 gram of onion skin gives 17,1 gram of extract. On qualitative phytochemical examinations the extract contains flavonoids using thin layer chromatography and from quantitative examination 1 gram of extract yields 27.7% quercetin. In this experiment 18 rats were divided into six groups and each groups consist of three rats. The normal control of rat showed no histologic abnormalities (Figure 1 and 2) and scored 0. The negative control were only induced with CFA showed many inflammatory cellular infiltration, with neutrophil and macrophage, thickened membrane of cartilage and there is an erosion (figure 3) we scored with 3 and 2 (data showed in table 1). Sections from the right knees of positive control were treated with sodium diclofenac showed no histologic abnormalities but there is thickened of cartilage membrane. From 3 rats in positive control there are one rat has many inflammatory cellular infiltration, so it scored 2 (figure 4). The group of rat who treated with extract in doses 100, 200, 300 mg/kg body weight showed no

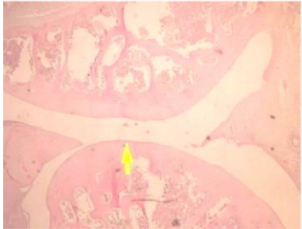
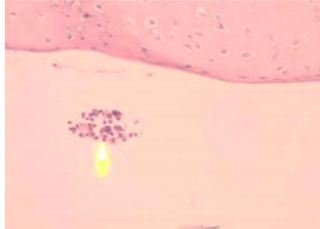
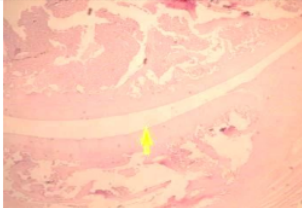

histologic abnormalities, but some rat from group treated with 100 and 200 mg/kg body weight had some inflammatory cell infiltration in the synovial membrane with no significant thickened of the membrane of cartilage or cartilage erosion were scored 1 (figure 7,9,11). All of rat in group 300 mg/kg body weight showed no histological abnormalities, there is no erosion, an no thickened membrane of cartilage.

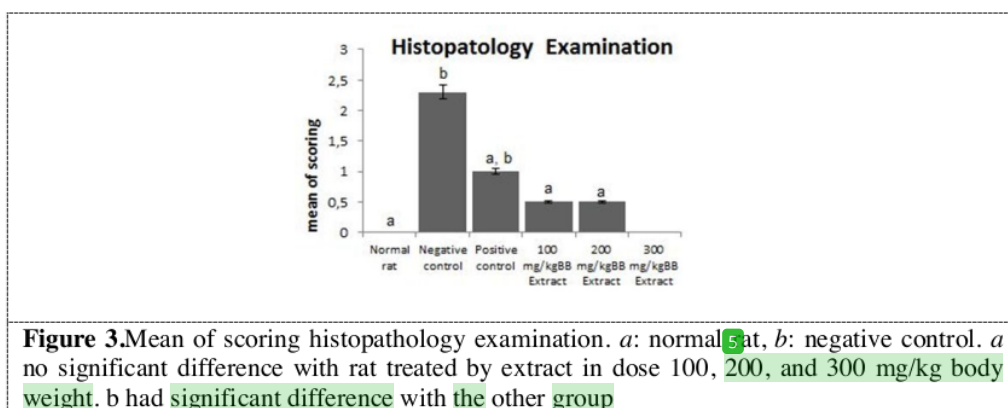
Normal rat no significant difference with rat treated by extract in dose 100, 200, and 300 mg/kg body weight. While the negative control have significant difference with the other group. Analyze with SPSS 21 Mann-Whitney U test, onion skin extract was significantly reduced joint pathology on the histopathological changes in the joint of rat while sodium diclofenac was not effective ( $P < 0.05$ ). The normal control group of rat have no significant difference with the rat treated by extract 100,200 and 300 mg/kg body weight. Its mean that onion skin extract can reduce the inflammatory cell infiltration , fixed the erosion and fibrosis and made it become normal.

Table 1: Histopathology score of inflammatory cell infiltration, erosion, cartilage membrane and fibrosis on 6 group

Sample code (mg/kg bodyweight)	Inflammatory cell	Cartilage membrane ( $\mu\text{m}$ )	Erosion	Fibrosis	score
Normal 1	-	25	-	-	0
Normal 2	-	19	-	-	0
Normal 3	-	30	-	-	0
Negative control 1	+	55	+	+	2
Negative control 2	+	32	+	+	2
Negative control 3	+++	40	+	+	3
Positive control 1	-	79	-	-	0
Positive control 2	++	20	+	+	2
Positive control 3	-	95	-	-	0
100 (1)	-	25	-	-	0
100 (2)	+	44	-	-	1
100 (3)	-	52	-	-	0
200 (1)	+	41	-	-	1
200 (2)	-	47	-	-	0
200 (3)	-	38	-	-	0
300 (1)	-	72	-	-	0
300 (2)	-	40	-	-	0
300 (3)	-	59	-	-	0

	
<p><b>Figure 1.</b> Histopathology 100x the knee of the Normal rat without abnormalities on intraarticular (score 0)</p>	<p><b>Figure 2.</b> Histopathology 400x the knee of the Normal rat, no inflammation sign. (score 0)</p>
	
<p><b>Figure 3.</b> Histopathology 100x, the negative control showed significant thickened and fibrosis of the joint capsule, involvement of the articular cartilage, appearance of inflammatory cells in the joint space (yellow row) (score 3)</p>	<p><b>Figure 4.</b> Histopathology 400x, the negative control showed significant thickened and fibrosis of the joint capsule, involvement of the articular cartilage, appearance of inflammatory cells in the joint space (yellow row) (score 3)</p>
	
<p><b>Figure 5.</b> Histopathology 100x, as the positive control showed no inflammatory cells in the joint space (yellow row)</p>	<p><b>Figure 6.</b> Histopathology 400x, as the positive control, no inflammatory cells in the joint space no detectable abnormalities but thickened of membrane (yellow row)</p>
	
<p><b>Figure 7.</b> Histopathology 100x, the rat group treated with 100 mg onion skin extract showed inflammatory cells in the</p>	<p><b>Figure 8.</b> Histopathology 400x, the rat group treated with 100 mg onion skin extract showed small number of inflammatory cells</p>

<p>joint space (yellow row) (score 1)</p> 	<p>in the joint space (yellow row) (score 1)</p> 
<p><b>Figure 9.</b> Histopathology 100x, the rat group treated with 200 mg onion skin extract showed minimal inflammatory cells in the joint space (score 1)</p>	<p><b>Figure 10.</b> Histopathology 400x, the rat group treated with 200 mg onion skin extract showed small number of inflammatory cells in the joint space (yellow row) (score 1)</p>
	
<p><b>Figure 11.</b> Histopathology 100x, the rat group treated with 300 mg onion skin extract showed there was no inflammatory cells in the joint space, absent of thickened membrane and fibrosis on the joint capsule, no involvement of the articular cartilage (score 0)</p>	<p><b>Figure 12.</b> Histopathology 400x, the rat group treated with 300 mg onion skin extract showed absent of thickened and fibrosis on the joint capsule, no involvement of the articular cartilage and clean of inflammatory cells in the joint space (yellow row) (score 1)</p>



Normal rat no significant difference with rat treated by extract in dose 100, 200, and 300 mg/kg body weight. While the negative control have significant difference with the other group.

Analyze with SPSS 21 Mann-whitney U test, onion skin extract was significantly reduced joint pathology on the histopathological changes in the joint of rat while sodium diclofenac was not effective with p value ( $p=0,005$ ). The normal control group of rat have no significant difference with the rat treated by extract 100,200 and 300 mg/kg body weight. Its mean that onion skin extract can reduce the inflammatory cell infiltration, fixed the erosion and fibrosis and made it become normal.

#### 4. DISCUSSION

Rheumatoid Arthritis (RA) is an autoimmune disease with chronic inflammation characterized by inflammation of synovial tissue in some joints. RA will trigger joint destruction through an inflammatory process involving the synovial membrane, cartilage, and subchondral bone [10]. Oxidant stress plays a very important role in the pathogenesis of Rheumatoid arthritis disease.

In arthritis patients found increased lipid peroxidation and decreased enzymatic and non enzymatic antioxidants. Complete Freund's Adjuvant (CFA) Complete induction leads to an inflammatory response to the rheumatoid arthritis model [11]. CFA triggers the formation of Reactive Oxygen Species (ROS) and free radicals. Free radicals can damage lipid cell membranes, DNA and proteins that cause cell oxidative stress [12]. The oxidative stress mediated by this proinflammatory cytokine protein can be determined by measuring the levels of Interleukin 8 (IL-8) [13].

The ethanol onion skin extract has significant anti-arthritis effect, as it inhibited the CFA-induced inflammatory cells, erosion of joint cartilage and bone destruction. These results support the use of onion skin extract a herbal medicine for the treatment of inflammatory disorders and rheumatoid arthritis.

Onion skin extract contains non-nutritional substances (phytochemicals). Phytochemical compounds contained in red onion are phytosterol, flavonol, flavonoid, quercetin glycoside, pectin, saponin, etc. Red onion skin contains high antioxidants even more than the onion itself. According to research, onion skin has antioxidants consisting of flavonoid and polyphenol derivatives. One of the most famous polyphenols has many properties is quercetin [14]. Quercetin is a polyphenol derivative found in the skin of red onion. The content of quercetin in red onion skin is very high, as evidenced by previous research extracting onion skin with microwave assisted extraction (MAE) method using 97% ethanol solvent with the result found that in 1 gram of onion skin has  $4.75 \pm 0.15$  mg quercetin [7].

Previous studies have also evaluated the anti-arthritis and anti-inflammatory properties of quercetin and found that Centipeda minima leaves extracts (25 mg/kgBW) exhibits significant anti-inflammatory and anti-arthritis activity in carageenan induce in rats [15]. However, they used carageenan as an induction of arthritis, whereas in our study CFA and shallot peel extract were used for quercetin isolation. So that it has the advantage in the future that the red onion skin can be used as a raw material in the manufacture of medicine and no longer becomes a waste.

Our study revealed that the plant extract had anti-arthritis properties in CFA-induced mice. Apart from allium cepa extract, Costus speciosus extract also has anti-arthritis properties. Based on research conducted by Srivastava et al, Costus speciosus has significant anti-arthritis properties. The methanolic extract of Costus speciosus in doses of 400 and 800 mg / kg showed 75.50% and 68.33% protection against increase in paw edema, respectively. Costus speciosus showed dose-dependent action in all the experimental models [16]. There are several limitation of this study such as potential in addressing only for symptom of

arthritis but not responsible in addressing the underlying cause of arthritis, number of sample size related with increases the margin of error and used post only control group design without pre test. Further studies required to involving animals with joint size and structure closer to humans and needed to find the appropriate dose for red onion skin extract

## 5. CONCLUSION

In summary, this study showed that onion skin extract given orally to rat, prevents some principal signs of arthritis and significantly reduces the joint damage caused by induced with Complete Freund's Adjuvant immune-mediated monoarthritic arthritis in rats. Onion skin extract have therapeutic benefit than non steroidal antiinflammatory drugs.

### Acknowledgments

Authors wishing to acknowledge assistance or encouragement from Akbar, S.Si Apt for supplying the Complete Freund's Adjuvant (CFA) and Upik Anderiani for expert in the histologic scoring of knee joint samples.

## REFERENCES

- [1] Meyer M, Jesson M I, Li X, Elrick M M, Shippy C L F, Warner J D, Gross C J, Dowty M E, Ramaiah S K, Hirsch J L, Saabye M J, Barks J L, Kishore N, Morris D L 2010 *Anti-inflammatory activity and neutrophil reductions mediated by the JAK1/JAK3 inhibitor, CP-690,550 in rat adjuvant-induced arthritis* **7** p 41
- [2] Sweeney S E, Firestein G S 2004 *Rheumatoid arthritis: Regulation of synovial inflammation*. **36** p 372-378
- [3] American College of Rheumatology 2012 *Rheumatoid arthritis*
- [4] Nainggolan O 2009 *Prevalensi dan Determinan Penyakit Rematik di Indonesia*. Puslitbang Biomedis dan Farmasi Badan Penelitian dan Pengembangan Kesehatan Departemen Kesehatan. **59** p 588-594
- [5] Wolfe F and Hawley D J 2000 *The comparative risk and predictors of adverse gastrointestinal events in rheumatoid arthritis and osteoarthritis: a prospective 13 year study of 2131 patients* **7** p 1668-1673
- [6] Dewi T S and friends 2015 *Aktivitas Antiinflamasi Ekstrak Eter Kulit Batang Tenggulun terhadap Edema pada Tikus Wistar yang Diinduksi dengan Karagenan* **9** p 13-19
- [7] Jin E, Lim S, Kim S, Park Y, Jang J, Chung M, Park H, Shim K, Choi Y 2011 *Optimization of various extraction methods for quercetin from onion skin using response surface methodology* **20** p 1727-1733
- [8] Zuyi W, Bodi Z, Shahrzad A, Nikolaos S, Alan B, Xueyan F, Alexandra K K, Christina A, and Theoharis C T 2012 *Quercetin Is More Effective than Cromolyn in Blocking Human Mast Cell Cytokine Release and Inhibits Contact Dermatitis and Photosensitivity in Humans* **7** (e33805)
- [9] Torres-Guzman AM, Urbina C, Vazques P, Gonzales R, Pina A, Ruis R, and Andrade M 2014. *Chronic oral or intraarticular administration of docosahexaenoic acid reduces nociception and knee edema and improves functional outcomes in a mouse model of Complete Freund's Adjuvant-induced knee arthritis*. *Arthritis Research & Therapy* 2014, **16**:R64
- [10] Vijaylaxmi A, Bakshi V, Begum N 2015 *Anti-Arthritic and Anti Inflammatory Activity of Beta Caryophyllene against Freund's Complete Adjuvant Induced Arthritis in Wistar Rats* **9** p 2
- [11] Ramani Y R 2012 *Antiarthritic Activity of Acetone Extract of Terminalia Chebula*. *Berhampur: India* **3** p 1-9

- [12] Valko M 2006 *Free Radical, Metal And Antioxidant In Oxidative Stress Induced Cancer, J.Chem-Biol*, Rusia, edisi **160**, p 1-40
- [13] Georganas C, Liu H, Perlman H, Hoffmann A, Thimmapaya B , Pope R M 2000 *Regulation of IL-6 and IL-8 expression in rheumatoid arthritis synovial fibroblasts*. **165** p 7199-7206
- [14] Siti R, Nunung K, Vina A 2005 *Ekstraksi Dan Identifikasi Senyawa Flavonoid Dari Limbah Kulit Bawang Merah Sebagai Antioksidan Alami* **2** p 1
- [15] Srivastava S, Singh P, Jha KK, Mishra G, Srivastava S, Khosa RL 2012 *Evaluation of anti-arthritis potential of the methanolic extract of the aerial parts of Costus speciosus*. *J Ayurveda Integr Med.* **3** p 204-208.
- [16] Sarkar A, Tripathi VD, Sahu RK 2017 *Anti-inflammatory and Anti-arthritis Activity of Flavonoids Fractions Isolated from Centipeda minima Leaves Extracts in Rats* **7** p 231

# Anti-Arthritic Effect Of Onion Skin Extract On Rat Complete Freund's Adjuvant-Induced

## ORIGINALITY REPORT

**21** %  
SIMILARITY INDEX

**17** %  
INTERNET SOURCES

**13** %  
PUBLICATIONS

**8** %  
STUDENT PAPERS

## PRIMARY SOURCES

<b>1</b>	Submitted to King Saud bin Abdulaziz University for Health Sciences Student Paper	<b>3</b> %
<b>2</b>	<a href="http://ijpsr.com">ijpsr.com</a> Internet Source	<b>3</b> %
<b>3</b>	<a href="http://www.ncbi.nlm.nih.gov">www.ncbi.nlm.nih.gov</a> Internet Source	<b>3</b> %
<b>4</b>	<a href="http://www.gssrr.org">www.gssrr.org</a> Internet Source	<b>2</b> %
<b>5</b>	<a href="http://repository.futminna.edu.ng:8080">repository.futminna.edu.ng:8080</a> Internet Source	<b>2</b> %
<b>6</b>	<a href="http://www.rheumatology.org">www.rheumatology.org</a> Internet Source	<b>2</b> %
<b>7</b>	<a href="http://www.tandfonline.com">www.tandfonline.com</a> Internet Source	<b>1</b> %
<b>8</b>	Submitted to Universitas Negeri Surabaya The State University of Surabaya Student Paper	<b>1</b> %

9	Submitted to UW, Madison Student Paper	1 %
10	bone.imedpub.com Internet Source	1 %
11	josr-online.biomedcentral.com Internet Source	1 %
12	docksci.com Internet Source	1 %
13	H Karim, A Ahmad, R Natzir, M N Massi, R Arfah, N Asmi, A Karim. " Isolation and identification of bioactive proteins from the brown algae Sp. and their potential as anticancer agents ", Journal of Physics: Conference Series, 2019 Publication	1 %
14	scialert.net Internet Source	1 %

Exclude quotes  On

Exclude matches  < 1%

Exclude bibliography  On