

One-year stability of the mandibular advancement and counterclockwise rotation for correction of the skeletal class II malocclusion and high mandibular plane angle: Dental and skeletal aspect

by

Submission date: 05-Apr-2023 10:33AM (UTC+0700)

Submission ID: 2056264043

File name: Paper_5_One_Stability.pdf (1.03M)

Word count: 5276

Character count: 28355



ScienceDirect

Biomedical Journal

journal homepage: www.elsevier.com/locate/bj

Original Article

One-year stability of the mandibular advancement and counterclockwise rotation for correction of the skeletal class II malocclusion and high mandibular plane angle: Dental and skeletal aspectMuhammad Ruslin^{a,*,**}, Andi Sitti Hajrah Yusuf^{a,b}, Tymour Forouzanfar^c, Rokus Barendregt Greebe^c, Dirk Bram Tuinzing^c, Sri Astuti Thamrin^d, Paolo Boffano^e, Lun-Jou Lo^{f,g,*}^a Department of Oral and Maxillofacial Surgery Faculty of Dentistry, Hasanuddin University, Makassar, Indonesia^b School of Dentistry, College of Oral Medicine, Taipei Medical University, Taipei, Taiwan^c Department of Oral and Maxillofacial Surgery/Oral Pathology, VU University Medical Center/Academic Center for Dentistry Amsterdam (ACTA), Amsterdam, The Netherlands^d Department of Statistics, Hasanuddin University, Makassar, Indonesia^e Division of Maxillofacial Surgery, "Maggiore della Carità" University Hospital, University of Eastern Piedmont, Novara, Italy^f Department of Plastic and Reconstructive Surgery, Craniofacial Research Center, Chang Gung Memorial Hospital at Linkou, Taoyuan, Taiwan^g College of Medicine, Chang Gung University, Taoyuan, Taiwan

ARTICLE INFO

Article history:

Received 6 April 2020

Accepted 7 February 2021

Available online 13 February 2021

Keywords:

Counterclockwise

Dental and skeletal

High mandibular plane angle

Mandibular deficiency

ABSTRACT

Background: The purpose of this study was to evaluate the stability on dental and skeletal aspect after surgical advancement and counterclockwise rotation for the correction of the mandibular deficiency in patients with high mandibular plane angle (MPA).**Methods:** We analyzed the records of patients who had undergone surgical treatment for dentofacial deformities with mandibular deficiency and high MPA. Clinical and radiological data were taken 1 month before surgery (T0), 6 weeks after surgery (T1) and 1 year after surgery (T2). Cephalometric values of the MPA were recorded and compared. The cephalometric changes in the different time periods were defined as follows: A postsurgical changes (T0–T1), B one-year changes (T1–T2), and C short term changes (T0–T2).**Results:** Twenty patients had prominent mandibular deficiency with an MPA of over 35° (high angle). The mean age of patients at surgery was 29.7 years. Seven patients had a single jaw procedure, 20 patients had bilateral sagittal split osteotomy (BSSO) combined with a Le Fort I osteotomy and 14 patients had additional genioplasty. MPA values differed^{*} Corresponding author. Department of Plastic & Reconstructive Surgery, Chang Gung Memorial Hospital at Linkou, 5, Fusing St., Gueishan, Taoyuan 333, Taiwan^{**} Corresponding author. Department of Oral and Maxillofacial Surgery, Faculty of Dentistry, Hasanuddin University, Jl. Perintis Kemerdekaan KM 10, Makassar, South Sulawesi 90425, Indonesia.E-mail addresses: mruslin@unhas.ac.id (M. Ruslin), lunjoulo@cgmh.org.tw (L.-J. Lo).

Peer review under responsibility of Chang Gung University.

<https://doi.org/10.1016/j.bj.2021.02.005>2319–4170/© 2021 Chang Gung University. Publishing services by Elsevier B.V. This is an open access article under the CC BY-NC-ND license (<http://creativecommons.org/licenses/by-nc-nd/4.0/>).

significantly between the time periods ($p < 0.05$) with an observed relapse of the angle. However, satisfactory clinical improvement was achieved in the dental and skeletal presentation. The overjet improvement was evident from 8.815 ± 2.085 mm (T0) to 3.426 ± 1.253 mm (T2).

Conclusion: Counterclockwise surgical advancement of the mandible to correct mandibular deficiency in patients with a high mandibular plane angle showed an overall acceptable stability during one year follow-up.

At a glance commentary

Scientific background on the subject

This study evaluated a group of patients with class II malocclusion and mandibular deficiency presenting with high mandibular plane angle. Orthognathic surgery using mandibular advancement and counterclockwise rotation was performed. Postoperative stability was adequate and the results were good after one year assessment.

What this study adds to the field

Dentofacial deformity with prominent overjet, class II malocclusion and high mandibular plane angle is considered difficult to correct. However, adequate orthognathic surgical technique with mandibular advancement, counterclockwise rotation, and appropriate fixation could achieve good outcome. Relapse of the angle was observed, but clinical improvement was accomplished.

A facial morphology with a mandibular deficiency is one of the common types of dentofacial deformities requiring orthognathic surgery in Caucasian population, such as in the Netherlands [1-4]. In orthodontic literature this deformity is classified as class II which consists of two highly different deformities namely the low angle short face type and the high mandibular plane angle (MPA) type [5]. These two types of deformity differ with regard not only to facial appearance, but also to facial behavior after surgical orthodontic treatment [1,5,6]. Mandibular advancement surgery in convergent, deep-bite cases results in a clockwise movement of the jaw that increases the anterior facial height. In contrast, mandibular advancement surgery in the divergent type with a tendency to open bite leads to a counterclockwise rotation that closes the open bite and reduces the anterior facial height [1,5,6].

One of the main challenges in orthognathic surgery especially in class II cases is the stability after large advancement with counterclockwise rotation [7]. Nowadays, there is still considerable debate on the effects of counterclockwise rotation of the mandible. Moreover, it is still controversial whether this procedure is a clinically stable procedure [8]. Many

authors consider that although it may be desirable to rotate the MPA counterclockwise to alter the facial height and obtain a better esthetic result, this movement is both unstable and unpredictable [9-13]. Numerous publications support the view that skeletal responses vary in high-angle and low-angle class II patients, with the high-angle MPA patients having a higher frequency, greater magnitude and more continuous pattern of relapse [2,13,14]. While various studies have reported a positive association between high MPA and condylar resorption as a cause of late relapse [3,4,15,16], others have claimed that the advancement surgery does lead to stable results if proper account is taken of the necessary precautions regarding temporomandibular joint (TMJ) repair, joint medication, and muscle-relaxing techniques or medication [17-20]. This study was performed to investigate the skeletal and dental stability after the mandibular advancement surgery in patients with high MPA.

Materials and methods

This study involved patients who had pre- and postoperative orthodontic and orthognathic treatment at the Department of Oral and Maxillofacial Surgery/Oral Pathology at VU University Medical Center Amsterdam, the Netherlands. Surgical advancement was accomplished in all patients by means of bilateral sagittal split osteotomy (BSSO) with the modification according to Hunsuck, with or without a Le Fort I osteotomy or genioplasty. All surgical procedures had been performed by a single surgeon (DBT) at the same hospital. Only patients with prominent mandibular deficiency and a high MPA ($>35^\circ$) were included. Patients with syndromes, cleft lip and/or palate, or post-traumatic conditions were excluded. Data collection and analyses were achieved through the collaborative forces.

Data collection

The retrospective database at the department included all patients who underwent orthognathic surgical treatment for maxillofacial deformity. The following information were reviewed: age, gender, age at the time of surgery, type of deformity, type of surgery, and cephalometric analysis during the various follow-up periods. Patients were contacted and agreed to participate in the present study. Permission for this study was given by the Ethical Committee at VU University Medical Center, Amsterdam, the Netherlands and in accordance with the Declaration of Helsinki.

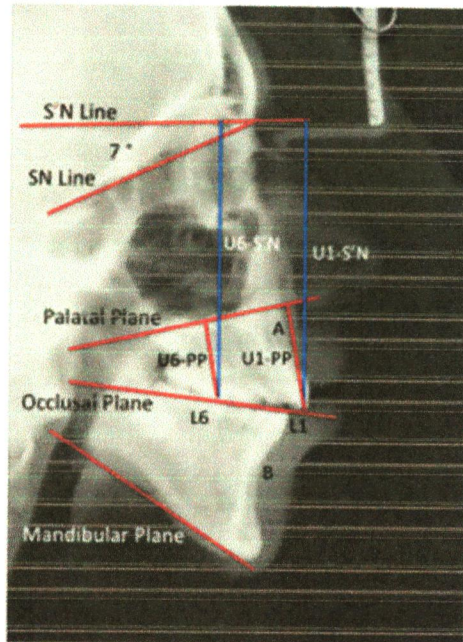


Fig. 1 Skeletal landmarks and the reference lines and planes used in the cephalometric analysis.

Cephalometric analysis

The lateral cephalometric radiographs were taken using a standard radiographic technique by centric relation, with the Frankfort horizontal plane parallel to the floor. The evaluation and follow-up periods were as follows: T0, 1 month before the jaw surgery; T1, 6 weeks postoperatively; and T2, 1 year postoperatively. The cephalometric changes in different time periods were defined as follows: A, early postsurgical changes (T0–T1); B, one-year changes (T1–T2); C, short term changes (T0–T2).

In this study, all standard lateral cephalometric radiographs were hand-traced on acetate paper by the same examiner (MR). A horizontal reference line (S'N) was constructed using a line through the Nasion rotated 7° from the Sella-Nasion (SN) line. The maxillary landmarks were the A point, the Anterior Nasal Spine (ANS), the Posterior Nasal Spine (PNS), the incisal edge of the maxillary central incisor (U1), and the mesiobuccal cusp tip of the maxillary first molar (U6). The Mandibular landmarks were the B point, the Menton (Me), the Gonion (Go), the incisal edge of the mandibular central incisor (L1), and the mesiobuccal cusp tip of the mandibular first molar (L6). The following angular or planes were used: the horizontal reference line (S'N), the Sella-Nasion line, the Palatal Plane (PP) (i.e., ANS–PNS), the Occlusal Plane (OP) (i.e., U1–U6), and the Mandibular Plane (MP) (i.e., Me–Go). Horizontal maxillary movements were assessed using the angular variables SN–A and SN–PP. Vertical maxillary movements were measured using the linear variables U1–S'N and U6–S'N. Vertical dental movements were measured using the linear variables U1–PP and U6–PP. The mandible was assessed using the angular variables SN–B, PP–OP, PP–MP, OP–MP, and the MPA (i.e., SN–MP). The overjet is the distance between two lines drawn from U1 and L1 perpendicular to S'N. The overbite is the distance between two lines drawn from U1 and L1 parallel to S'N.

Surgical approach

The Le Fort I osteotomy involves down-fracture, trimming and repositioning of the maxilla to obtain the desired position. Rigid fixation of the maxilla was then achieved using either four titanium mini-plates (Straight and L type, KLS Martin, Germany) in the lateral and anterior regions, or two titanium mini-plates in the anterior regions and two wires in the posterior regions.

The BSSO in the original procedures was performed bilaterally. The split osteotomy was made in the region of the first or second molar. The teeth were placed in their planned

Table 1 Means and standard deviations 1 month preoperatively (T0), 6 weeks post-operatively (T1), and 1 year post-operatively (T2).

Parameter	T0		T1		T2		p-value
	N	(Mean ± SD)	N	(Mean ± SD)	N	(Mean ± SD)	
SNA (°)	27	(80.574 ± 4.351)	27	(83.389 ± 4.669)	27	(82.389 ± 4.882)	0.084 ^a
SN–PP (°)	27	(5.296 ± 2.856)	27	(7.704 ± 4.098)	27	(7.574 ± 3.817)	0.018 ^b
1–S'N (mm)	27	(82.667 ± 4.357)	27	(82.037 ± 3.637)	27	(81.667 ± 4.940)	0.254 ^b
6–S'N (mm)	27	(76.778 ± 4.041)	27	(75.167 ± 3.716)	27	(72.982 ± 4.584)	0.363 ^b
1–PP (mm)	27	(32.296 ± 3.826)	27	(31.796 ± 3.271)	27	(32.148 ± 3.019)	0.857 ^b
6–PP (mm)	27	(25.037 ± 2.714)	27	(25.667 ± 2.780)	27	(25.907 ± 2.531)	0.471 ^b
SNB (°)	27	(74.519 ± 4.902)	27	(78.111 ± 4.302)	27	(76.981 ± 4.558)	0.017 ^b
PP–OP (°)	27	(10.982 ± 4.307)	27	(10.204 ± 3.704)	27	(10.074 ± 4.615)	0.696 ^a
PP–MP (°)	27	(32.778 ± 4.978)	27	(28.889 ± 5.586)	27	(31.093 ± 5.639)	0.035 ^b
OP–MP (°)	27	(21.889 ± 5.462)	27	(18.963 ± 5.709)	27	(20.648 ± 4.938)	0.141 ^b
SN–MP (°)	27	(39.444 ± 3.451)	27	(36.907 ± 4.513)	27	(38.519 ± 5.081)	0.534 ^b
Overjet (mm)	27	(8.815 ± 2.085)	27	(2.074 ± 1.466)	27	(3.426 ± 1.253)	0.000 ^b
Overbite (mm)	27	(2.704 ± 1.958)	27	(1.574 ± 1.044)	27	(1.537 ± 0.843)	0.003 ^b

^a Repeated measures ANOVA.

^b Friedman test.

position using surgical splints. Each condyle was flexibly placed in the glenoid fossa and the ramal segments were fixed with titanium mini-plates that were applied intraorally on each side using four monocortical titanium screws. Each screw was 2 mm in diameter and 5 mm in length. Intermaxillary fixation (IMF) was maintained with a rubber elastic for an average of 14 days [21].

Genioplasty was usually performed in combination with the orthognathic surgery. The incision was made between the first and second pre-molars just below the mucogingival junction, and was extended through the periosteum. The line of the bone incision was marked using a fine fissure bur and the osteotomy was continued with a saw. The segment was mobilized and fixed with the wire osteosynthesis [21].

Statistical method

Before doing further statistical analysis, we run the distribution test using Kolmogorov smirnov for the variants in all groups. The statistical analysis conducted for normally distributed data was repeated measures ANOVA, while for not normally distributed data using Friedman test. Both analyses are used to evaluate value changes T0, T1 and T2. p values less than 0.05 (alpha 5%) were considered significant. The Wilcoxon test (for not normally distributed data) and Bonferromi test (for normally distributed data) were used to determine difference in time periods for A. postsurgical changes (T0-T1), B. one-year changes (T1-T2), and C. short term change (T0-T2). All data were transferred to SPSS version 22 (IBM Corp. Armonk, NY, USA).

Results

The study included 27 patients (26 females and 1 male). All patients had a mandibular deficiency with an MPA higher than 35. The mean age at the time of surgery was 29.7 ± 8.9 (range 18-45 years). Seven cases were treated with a single jaw BSSO. In 20 cases surgical advancement of the mandible had been combined with a Le Fort I osteotomy, and in 14 cases, it had been combined with a genioplasty. In 20 patients, rigid screw fixation was used by 3 bicortical positioning screws (2 mm) at the upper border of the mandible without IMF. Seven patients had combined 2 titanium mini-plates in the anterior regions and stainless steel wire fixation in the posterior regions.

Table 1 presents the means and standard deviations of each variable measured in three timings at T0, T1, and T2. The mean ± the standard deviation for the follow up time on each T0, T1 and T2 are 37.97 ± 29.49, 37.21 ± 30.65, and 37.63 ± 30.25, respectively. Patients in this group showed characteristics of class II malocclusion with severe overjet (8.815 ± 2.085 mm) and high MPA (SN-MP: 38.519 ± 4.505°). The cephalometric changes in these patients revealed a statistically significant difference in dental and skeletal aspects during the follow up times (p < 0.05). Majority of patients demonstrated to have the counterclockwise rotation during the orthognathic surgery by the early postoperative SN-MP angle (37.037 ± 4.534°) six weeks after the operation. The

Table 2 Mean difference of time periods: A. postsurgical change, B. one-year change, and C. short term change.

Parameter	T0-T1			T1-T2			T0-T2		
	Mean difference	95% confidence interval Lower bound	Upper bound	Mean difference	95% confidence interval Lower bound	Upper bound	Mean difference	95% confidence interval Lower bound	Upper bound
SNA (°)	-2.815	-5.904	0.274	0.086	1.000	4.089	-1.815	-4.904	1.274
SN-PP (°)	-2.574	-4.937	-0.211	0.028	0.296	2.659	-2.278	-4.641	0.085
1-SN (mm)	0.630	-2.263	3.522	1.000	0.370	3.263	1.000	-1.893	3.893
6-SN (mm)	1.611	-1.139	4.361	0.467	-0.815	1.935	0.796	-1.953	3.546
1-PP (mm)	0.500	-1.757	2.757	1.000	-0.352	2.608	0.148	-2.108	2.405
6-PP (mm)	-0.630	-2.412	1.153	1.000	-0.241	2.023	-0.870	-2.653	0.912
SNB (°)	-3.593	-6.652	-0.533	0.016	1.130	4.189	-2.463	-5.522	0.596
PP-OP (°)	0.778	-2.036	3.592	1.000	0.130	2.944	0.907	-1.906	3.721
PP-MP (°)	3.889	0.287	7.491	0.030	-2.204	5.806	1.685	-1.917	5.287
OP-MP (°)	2.926	-0.656	6.508	0.147	-1.685	5.267	1.241	-2.341	4.823
SN-MP (°)	1.482	-1.901	4.864	0.862	-1.148	2.235	0.333	-3.049	3.716
Overjet (mm)	6.741	5.649	7.833	0.000	-1.352	-2.444	5.389	4.297	6.481
Overbite (mm)	1.296	0.420	2.173	0.001	-0.130	-1.006	1.167	0.290	2.043

^a Bonferromi test.
^b Wilcoxon test.

counterclockwise rotation of the mandible could also be validated by the reduction in angle between the palatal plane and mandibular plane (PP-MP: 28.889 ± 5.586) and between the occlusal plane and mandibular plane (OP-MP: 10.204 ± 3.704) after the orthognathic surgery. Relapse was noticed by the increase of the angles at one year postoperatively (PP-MP: 31.093 ± 5.640 , OP-MP: 20.648 ± 4.938). Both the SNA and SNB showed an increase after correction of the maxillofacial deformity (SNA: 83.389 ± 4.668 , SNB: 78.111 ± 4.302).

The treatment change of early postsurgical (A) one year after treatment (B), and short term (C) is shown in Table 2. Most of the angular changes between T0 and T1 were statistically significant ($p < 0.05$) showing the surgical movement for correction of the maxillofacial deformity. After one year (T1-T2), some of the changes could remain statistically significant ($p < 0.05$), but was minor in clinical consequence. The

overbite was maintained adequate without an appearance of open bite. The overjet was corrected and remained in the normal or acceptable range.

Figs. 2 and 3 show the individual values in the different time periods. Fig. 2 shows dentoskeletal changes of vertical dimension in the value of the 1-S'N and 6-S'N at follow-up times. Fig. 3 shows skeletal changes of the angular dimension in the value of the SN-PP, PP-MP, OP-MP, and SN-MP during follow-up times. Magnitude in the postoperative change and the 1-year change (relapse) were demonstrated. The changes in the mandibular plane angle varied (Fig. 3D). The majority of them showed minimal changes in MPA between the T1 and T2 periods, but a wide difference was observed in sporadic cases.

Fig. 4 shows the dental changes in the value of the 1-PP, 6-PP, Overjet, and Overbite during follow-up times of 1 month preoperatively, 6 weeks postoperatively, and 1 year

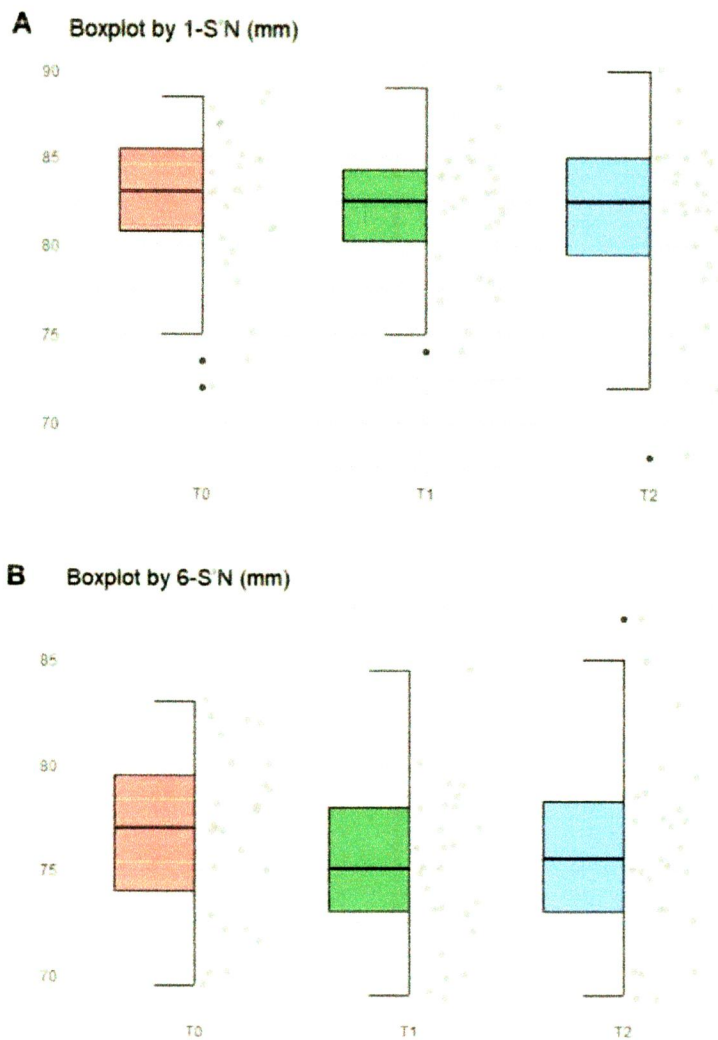


Fig. 2 Skeletal changes of vertical dimension in the value of the 1-S'N (A) and 6-S'N (B) at 3 follow-up times (T0) 1 month preoperatively (T1) 6 weeks postoperatively and (T2) 1 year postoperatively.

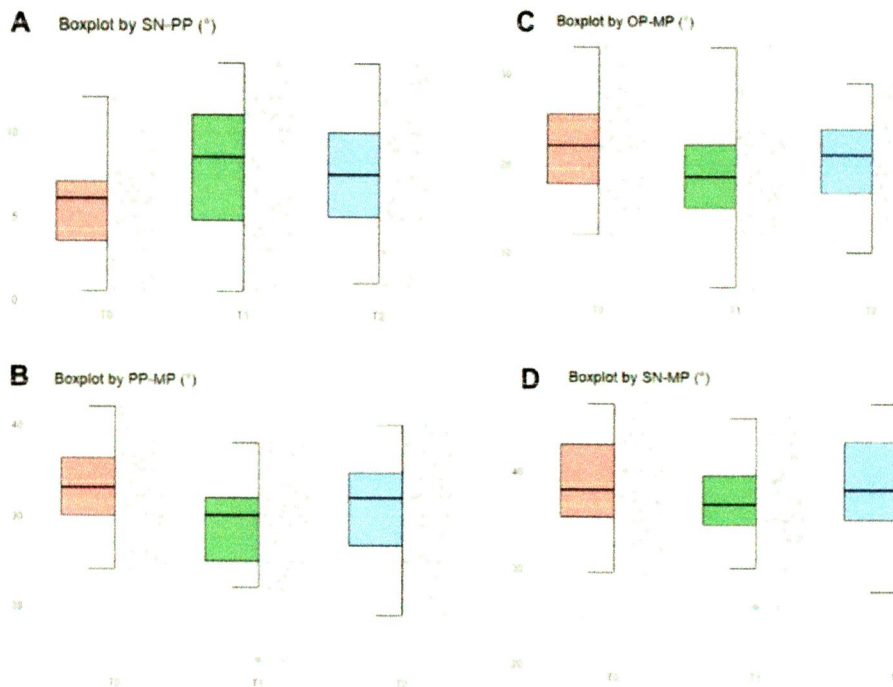


Fig. 3 Skeletal changes of angular dimension in the value of the SN–PP (A), PP–MP (B), OP–MP (C), SN–MP (D) during follow-up times (T0) 1 month preoperatively, (T1) 6 weeks postoperatively, (T2) 1 year postoperatively

postoperatively. No significant differences in the dental changes on 1 PP and 6 PP in both post surgical and 1 year periods (Fig. 4A and B). Improvement was observed in both overbite and overjet after the surgery (Fig. 4C and D). Overall the clinical outcome was satisfactory.

Discussion

Since the early years of orthognathic surgery, counterclockwise advancement of the mandible by a BSSO has not been considered to lead to stable results [1]. Initially, the instability was attributed to the fact of insecure fixation method, such as wires and intermaxillary fixation. It was thought that screw fixation would resolve the adverse effects of relapse. Arnett et al. [22] claimed stable results for rigid fixation, first with one plate, and more recently with two plates after mandibular advancement surgery [22]. As well as establishing good interdigitation, the use of long-term skeletal fixation is recommended. Medication is given to fight relapse caused by the unfavorable influence of muscles (Botox) and degeneration of the TMJ [17–19]. In a personal communication at the International Symposium on Orthognathic Surgery, Vienna, Austria 2010, Wolford LM, stated that muscles “do not play any role” in the occurrence of relapse, and that “fixing the condyles first” was the most important way of ensuring stable results after counterclockwise surgical movement of the mandible. In this study we found that although the occlusal stability was not always affected by the complete “return” of

the mandibular plane to the original position, the tendency was clearly observed.

The plausible causes of skeletal relapse from the BSSO procedure within 1 year may correlate indirectly to the surgery such as rotation of the ramus during surgery, the surgeon's experience, intersegmental movement, bone remodeling and remaining growth, density of bone, condylar displacement and condylar resorption [23–25]. According to previous systematic review and meta-analysis study, both horizontal and vertical stability of BSSO counterclockwise rotational advancement are significantly affected by the degree of rotation [6]. Supporting this study, another clinical research found out that “magnitude of mandibular advancement is a stronger surgical predictor for horizontal relapse at the B point, especially when the degree of mandibular advancement exceeded 8.5 mm [26]. In the case with high mandibular plane angle, skeletal relapse is predictably related to both counterclockwise rotation and myoskeletal balance that can happen during advancement [27]. Conversely, some previously published studies found that both large and small counterclockwise rotational advancement do not affect the postsurgical stability of the mandible after BSSO procedure [14,28]. Indeed, they suggested that this technique is a clinically stable procedure which coincides with the results in our present study.

Besides the magnitude of rotation, one systematic review from biomechanical studies suggested that the fixation method for the proximal and distal segments of mandible is another factor influenced the skeletal stability [29]. This finding contradicts the data found in a meta-analysis reported

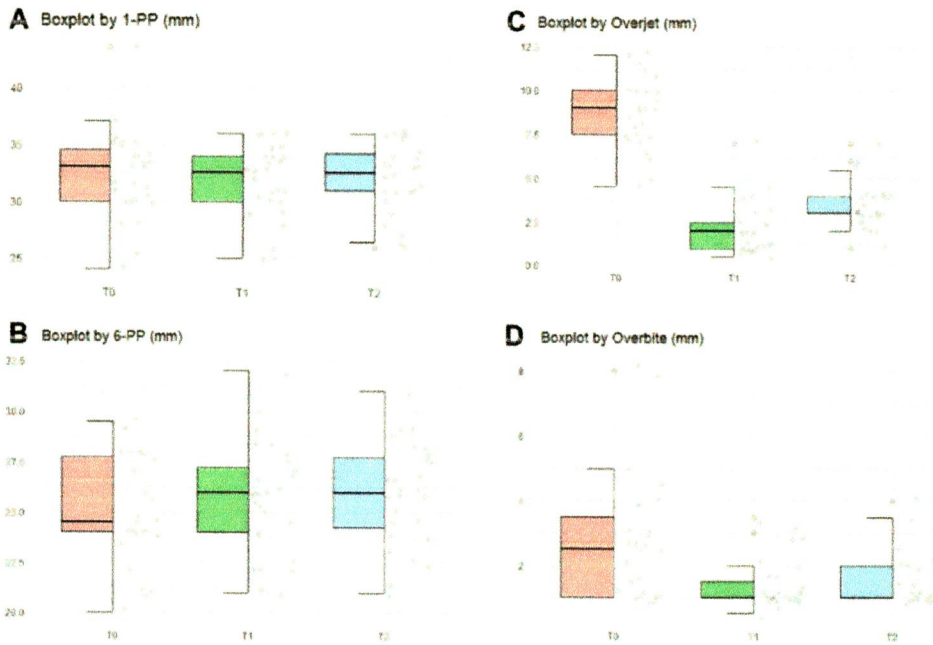


Fig 4 Dental changes in the value of the 1-PP (A), 6-PP (B), Overjet (C), Overbite (D) at 3 follow-up times (T0) 1 month preoperatively, (T1) 6 weeks postoperatively, and (T2) 1 year postoperatively.

that the method of fixation of the BSSO did not show statistically significant difference in skeletal stability following mandibular advancement surgery [30]. Underlining this result, based on the hierarchical scale of stability, the BSSO for mandibular counterclockwise rotation as well as BSSO with mandibular advancement are considered highly stable procedure regardless of the fixation method used [31]. However, both studies implied that the outcome of all preference methods highly depends on the surgeon experience [30,31].

It has been reported that surgical correction of the high MPA elongates the suprahyoid soft tissues and extends the pterygomasseteric sling causing posterior and inferior displacement of the distal segment of the mandible [1,10,12,32]. During follow-up time in 1 year, we found out that the MPA value was not much different from the preoperative MPA. This is consistent with the Eggenberger study [14], which was based on 12 years of follow-up and reported on the high-angle group. In its study, 70% of the total skeletal relapse occurred between 1 and 12 years postoperatively, contrasting with the process of skeletal relapse in the low-angle group which stopped after the first year of observation [14]. It has been reported that the counterclockwise rotation of the distal segment extends the pterygomasseteric sling posteriorly and elongates the suprahyoid musculature anteriorly, which can affect the mandibular stability [10]. Proffit et al. suggested that excellent stability required good neuromuscular adaptation [11]. However, we supposed that neuromuscular adaptation did not fully function after the counterclockwise repositioning of the mandible because the

gonial angle moved downwards and the chin rotated upwards preventing compensatory repositioning of muscles and other stretched soft tissues.

Our findings suggested that moving the distal segment upward and forward constituted an unstable mandibular movement. Interestingly, measurements on the MPA did not show difference in relapse between patients who had undergone single or double jaw osteotomies with a high MPA. This implied that patients with high mandibular plane angles are more likely remodeled to the initial value of the MPA. Whether the fixation methods with peri-surgical soft tissue management could improve the MPA would require further randomized control studies. However, the final outcome was satisfactory in this study with regard to the occlusion and facial aesthetics.

The main shortcoming of our study is its design as retrospective in nature. It is not possible to estimate the influence of any information bias resulting from this study. An immediate postoperative X-ray would better delineate the surgical effect, rather than the 6 weeks after the surgery. Certain skeletal movement or relapse could have occurred during the 6 weeks period. A second shortcoming is that the study included patients who had undergone single or double jaw surgery with different fixation modalities. The results need to be interpreted with care. But despite these shortcomings, our results demonstrate that these patients have an acceptable outcome from the procedure. More studies concerning these issues in patients with a high MPA would be required.

Conclusion

Counterclockwise surgical advancement of the mandible to correct a prominent mandibular deficiency in patients with a high mandibular plane angle showed acceptable results during a 1-year follow up. Although there was certain relapse in the mandibular plane angle during the follow up, the issue did not negatively influence the clinical outcome.

Conflicts of interest

No conflicting relationship exists for all authors

REFERENCES

- [1] Greebe RB, Tuinzing DB. Mandibular advancement procedures: predictable stability and relapse. *Oral Surg Oral Med Oral Pathol* 1984;57:13–6.
- [2] Bouwman JP, Tuinzing DB, Kostense PJ, Van Teeseling RA, Mokhtari H. The value of long-term follow-up of mandibular advancement surgery in patients with a low to normal mandibular plane angle. *Oral Maxillofac Surg* 1997;1:311–5.
- [3] Kerstens HC, Tuinzing DB, Gidding RP, Van der Kwast WA. Condylar atrophy and osteoarthritis after bimaxillary surgery. *Oral Surg Oral Med Oral Pathol* 1990;69:274–80.
- [4] Hoppenreijts TJ, Freihofer HF, Stoeltinga PJ, Tuinzing DB, van't Hof MA. Condylar remodelling and resorption after Le Fort I and bimaxillary osteotomies in patients with anterior open bite: a clinical and radiological study aesthetic and reconstructive surgery. *Int J Oral Maxillofac Surg* 1998;27:81–91.
- [5] Tuinzing DB, Greebe RB, Dorenbos J, Becking AG. Surgical orthodontics. Classification, diagnosis and treatment. *J Psychopathol Behav Assess* 2005, January;142 p.
- [6] Dicker GJ, Koolstra JH, Castelijns JA, Van Schijndel RA, Tuinzing DB. Positional changes of the masseter and medial pterygoid muscles after surgical mandibular advancement procedures: an MRI study. *Int J Oral Maxillofac Surg* 2012;41:922–9.
- [7] de Souza GM, Esteves LS, dos Santos JM, Zanetta-Barbosa D et al. Skeletal stability in orthognathic surgery: evaluation of methods of rigid internal fixation after counterclockwise rotation in patients with class II deformities. *Br J Oral Maxillofac Surg* 2015;53:730–5.
- [8] Hasprayoon S, Liao YF, Hsieh YJ. Skeletal stability after mandibular counterclockwise rotational advancement for correction of skeletal class II deformity – a systematic review and meta-analysis. *J Evid Based Dent Pract* 2019;19:156–65.
- [9] Dolce C, Hatch JP, Van Sickle JE, Rugh JD. Five-year outcome and predictability of soft tissue profiles when wire or rigid fixation is used in mandibular advancement surgery. *Am J Orthod Dentofacial Orthop* 2003;124:249–56.
- [10] Ayoub AF, Stürups DR, Moos KF. Stability of sagittal split advancement osteotomy: single-versus double-jaw surgery. *Int J Adult Orthod Orthognath Surg* 1995;10:181–92.
- [11] Proffit WR, Turvey TA, Phillips C. Orthognathic surgery: a hierarchy of stability. *Int J Adult Orthod Orthognath Surg* 1996;11:191–204.
- [12] Van Sickle JE, Dolce C, Keeling S, Tiner BD, Clark GM, Rugh JD. Technical factors accounting for stability of a bilateral sagittal split osteotomy advancement wire osteosynthesis versus rigid fixation. *Oral Surg Oral Med Oral Pathol Oral Radiol Endod* 2000;89:19–25.
- [13] Mobarak KA, Espeland L, Krogstad O, Lyberg T. Mandibular advancement surgery in high-angle and low-angle class II patients: different long-term skeletal responses. *Am J Orthod Dentofacial Orthop* 2001;119:368–81.
- [14] Eggensperger N, Smolka K, Luder J, Iizuka T. Short- and long-term skeletal relapse after mandibular advancement surgery. *Int J Oral Maxillofac Surg* 2006;35:36–42.
- [15] Arpommaeklong P, Shand JM, Heggie AA. Skeletal stability following maxillary impaction and mandibular advancement. *Int J Oral Maxillofac Surg* 2004;33:656–63.
- [16] Bonstap WA, Stoeltinga PJ, Hoppenreijts TJ, Van't Hof MA. Stabilisation of sagittal split advancement osteotomies with miniplates: a prospective, multicentre study with two-year follow up, part I. Clinical parameters. *Int J Oral Maxillofac Surg* 2004;33:535–42.
- [17] Postnick JC, Fantuzzo JJ. Idiopathic condylar resorption: current clinical perspectives. *J Oral Maxillofac Surg* 2007;65:1617–23.
- [18] Gonçalves JR, Cassano DS, Wolford LM, Santos-Pinto A, Marquez IM. Postsurgical stability of counterclockwise maxilomandibular advancement surgery: affect of articular disc repositioning. *J Oral Maxillofac Surg* 2008;66:724–38.
- [19] Gunson MJ, Arnett CW, Milam SB. Pathophysiology and pharmacologic control of osseous mandibular condylar resorption. *J Oral Maxillofac Surg* 2012;70:1918–34.
- [20] Frey DR, Hatch JP, Van Sickle JE, Dolce C, Rugh JD. Alteration of the mandibular plane during sagittal split advancement: short- and long-term stability. *Oral Surg Oral Med Oral Pathol Oral Radiol Endod* 2007;104:160–9.
- [21] Ruslin M, Forouzanfar T, Astuti IA, Soemantri ES, Tuinzing DB. The epidemiology, treatment, and complication of dentofacial deformities in an Indonesian population: a 21-year analysis. *J Oral Maxillofac Surg Med Pathol* 2015;27:601–7.
- [22] Arnett CW. A redefinition of bilateral sagittal osteotomy (BSO) advancement relapse. *Am J Orthod Dentofacial Orthop* 1993;104:506–15.
- [23] Hoffmannova J, Foltan R, Vlk M, Klima K, Pavlikova C, Bulik O. Factors affecting the stability of bilateral sagittal split osteotomy of a mandible. *Prague Med Rep* 2008;109:286–97.
- [24] Joss CU, Vassalli IM. Stability after bilateral sagittal split osteotomy advancement surgery with rigid internal fixation: a systematic review. *J Oral Maxillofac Surg* 2009;67:301–13.
- [25] Rao SH, Selvaraj L, Lankupalli AS. Skeletal stability after bilateral sagittal split advancement and setback osteotomy of the mandible with miniplate fixation. *Craniofacial Trauma Reconstr* 2014;7:9–16.
- [26] Tabrizi R, Nili M, Aliabadi E, Pourdanesh F. Skeletal stability following mandibular advancement: is it influenced by the magnitude of advancement or changes of the mandibular plane angle? *J Korean Assoc Oral Maxillofac Surg* 2017;43:152–9.
- [27] Schwartz K, Rodrigo-Domingo M, Jensen T. Skeletal stability after large mandibular advancement (>10 mm) with bilateral sagittal split osteotomy and skeletal elastic intermaxillary fixation. *J Oral Maxillofac Res* 2016;7 e5.
- [28] Hasprayoon S, Liao YF. Large versus small mandibular counterclockwise rotation during bimaxillary surgical correction of class II deformities – a retrospective CBCT study on skeletal stability. *Clin Oral Investig* 2020;24:1779–88.
- [29] Bin LR, Ernica NM, Junior EAG, Griza G, Conci R, Nadal L. Evaluation of the different methods for fixation of sagittal ramus split osteotomy of the mandibular ramus in relation to stability for mandibular

- advancement: a systematic review. *J Adv Med Med Res* 2020;32:111–21.
- [30] Al-Moraissi E, Al-Hendi E. Are bicortical screw and plate osteosynthesis techniques equal in providing skeletal stability with the bilateral sagittal split osteotomy when used for mandibular advancement surgery? A systematic review and meta-analysis. *Int J Oral Maxillofac Surg* 2016;45:1195–200.
- [31] Haas Junior OL, Guijarro-Martinez R, de Sousa Gil A, da Silva Meirelles L, Scolan N, Munoz-Pereira ME, et al. Hierarchy of surgical stability in orthognathic surgery: overview of systematic reviews. *Int J Oral Maxillofac Surg* 2019;48:1415–33.
- [32] Cassmann CJ, Van Sickle JE, Thrash WJ. Causes, location, and timing of relapse following rigid fixation after mandibular advancement. *J Oral Maxillofac Surg* 1990;48:450–4.

One-year stability of the mandibular advancement and counterclockwise rotation for correction of the skeletal class II malocclusion and high mandibular plane angle: Dental and skeletal aspect

ORIGINALITY REPORT

20%

SIMILARITY INDEX

14%

INTERNET SOURCES

18%

PUBLICATIONS

5%

STUDENT PAPERS

PRIMARY SOURCES

1

repositoriosaludmadrid.es

Internet Source

1%

2

mobile.repository.ubn.ru.nl

Internet Source

1%

3

Kazem Dalaie, Nazanin Senagoo, Reza Tabrizi. "Does Maxillomandibular Counterclockwise Rotation Affect Surgical Stability in Class III Skeletal Patients with High Plane Angle? A Retrospective Longitudinal Study", Journal of Maxillofacial and Oral Surgery, 2021

Publication

1%

4

docplayer.net

Internet Source

1%

5

www.foar.unesp.br

Internet Source

1%

6

"Orthognathic Surgery", Wiley, 2016

Publication

1%

-
- 7 N. Eggensperger, K. Smolka, J. Luder, T. Iizuka. "Short- and long-term skeletal relapse after mandibular advancement surgery", International Journal of Oral and Maxillofacial Surgery, 2006
Publication 1 %
-
- 8 Submitted to University of Hong Kong
Student Paper 1 %
-
- 9 www.koreascience.or.kr
Internet Source 1 %
-
- 10 openaccess.leidenuniv.nl
Internet Source 1 %
-
- 11 Ching-Chung Liang, Yi-Hao Lin, Yao-Lung Chang, Shuenn-Dhy Chang. "Urodynamic and clinical effects of transvaginal mesh repair for severe cystocele with and without urinary incontinence", International Journal of Gynecology & Obstetrics, 2011
Publication <1 %
-
- 12 pdfs.semanticscholar.org
Internet Source <1 %
-
- 13 Wei-Jung Chang, Lai-Chu See, Lun-Jou Lo. "Time trend of incidence rates of cleft lip/palate in Taiwan from 1994 to 2013", Biomedical Journal, 2016
Publication <1 %
-

14	doi.org Internet Source	<1 %
15	Ghali E. Ghali, Jennifer E. Woerner, Stavan Patel. "Avoiding Surgical Complications in Orthognathic Surgery", Elsevier BV, 2017 Publication	<1 %
16	Fukui, K.. "Characteristics of mandibular advancement surgery dependent on lower facial height differences in study of skeletal Class II patients with long-term stability", Orthodontic Waves, 200703 Publication	<1 %
17	www.scielo.br Internet Source	<1 %
18	hal-pasteur.archives-ouvertes.fr Internet Source	<1 %
19	arena.slu.edu Internet Source	<1 %
20	ir.tdc.ac.jp Internet Source	<1 %
21	media.zwp-online.info Internet Source	<1 %
22	Submitted to Taipei Medical University Student Paper	<1 %

23 Xi, Tong, Ruud Schreurs, Bram van Loon, Martien de Koning, Stefaan Bergé, Theo Hoppenreijns, and Thomas Maal. "3D analysis of condylar remodelling and skeletal relapse following bilateral sagittal split advancement osteotomies", *Journal of Cranio-Maxillofacial Surgery*, 2015.
Publication

<1 %

24 bjgp.org
Internet Source

<1 %

25 Reza Tabrizi, Mahsa Nili, Ehsan Aliabadi, Fereydoun Pourdanesh. "Skeletal stability following mandibular advancement: is it influenced by the magnitude of advancement or changes of the mandibular plane angle?", *Journal of the Korean Association of Oral and Maxillofacial Surgeons*, 2017
Publication

<1 %

26 publisher.medfak.ni.ac.rs
Internet Source

<1 %

27 www.thieme-connect.com
Internet Source

<1 %

28 "Management of Obstructive Sleep Apnea", Springer Science and Business Media LLC, 2021
Publication

<1 %

Submitted to University of the Western Cape

29

Student Paper

<1 %

30

F. Øye, T. Bjørnland, G. Støre. "Mandibular osteotomies in patients with juvenile rheumatoid arthritic disease", *Scandinavian Journal of Rheumatology*, 2009

Publication

<1 %

31

omfsimpath.be

Internet Source

<1 %

32

search.bvsalud.org

Internet Source

<1 %

33

www.yumpu.com

Internet Source

<1 %

34

Eggensperger, N.. "Skeletal relapse after mandibular advancement and setback in single-jaw surgery", *Journal of Oral and Maxillofacial Surgery*, 200412

Publication

<1 %

35

Georgescu, Rareș, Maria Daniela Podeanu, Ioana Colcer, Gabriel Grigorescu, Marius Florin Coroș, Cosmin Moldovan, Agota Ilyes, Iulia Bârsan, Denisa Moncea, and Simona Stolnicu. "Wegener's Granulomatosis of the Breast with Peculiar Radiological Aspect Mimicking Breast Carcinoma", *The Breast Journal*, 2015.

Publication

<1 %

36 Goncalves, J.R.. "Postsurgical Stability of Oropharyngeal Airway Changes Following Counter-Clockwise Maxillo-Mandibular Advancement Surgery", Journal of Oral and Maxillofacial Surgery, 200605

Publication

<1 %

37 Hsing-I Chiang, Siew-Na Lim, Hsiang-Yao Hsieh, Mei-Yun Cheng et al. "Preliminary Asian experience of using perampanel in clinical practice", Biomedical Journal, 2017

Publication

<1 %

38 Yeji Lee, Seung-Weon Lim, Vania Chan, Pureum Hong, Sang-Baek Han, Hwa Sung Chae. "The surgical outcomes of anterior segmental osteotomy in Asian skeletal class II patients", Oral and Maxillofacial Surgery, 2023

Publication

<1 %

39 digitalservices.vermont.gov

Internet Source

<1 %

40 Marangoni, Sara, Elke Van de Castele, Anna Chiara Frigo, Stefano Fusetti, and Nasser Nadjmi. "Surgical treatment of class II dento-facial deformity during adolescence: Long-term follow-up", Journal of Cranio-Maxillofacial Surgery, 2016.

Publication

<1 %

41 Shinnosuke Nogami, Kensuke Yamauchi, Norihisa Satomi, Yoshihiro Yamaguchi, Sou

<1 %

Yokota, Yoko Abe, Tetsu Takahashi. "Risk factors related to aggressive condylar resorption after orthognathic surgery for females: retrospective study", CRANIO®, 2016
Publication

42 docksci.com <1 %
Internet Source

43 erepo.uef.fi <1 %
Internet Source

44 jorthod.maneyjournals.org <1 %
Internet Source

45 livrepository.liverpool.ac.uk <1 %
Internet Source

46 openanesthesiajournal.com <1 %
Internet Source

47 usermanual.wiki <1 %
Internet Source

48 worldwidescience.org <1 %
Internet Source

49 Mobarak, K.A.. "Mandibular advancement surgery in high-angle and low-angle class II patients: Different long-term skeletal responses", American Journal of Orthodontics & Dentofacial Orthopedics, 200104
Publication

50

O.L. Haas Junior, R. Guijarro-Martínez, A.P. de Sousa Gil, L. da Silva Meirelles et al.

"Hierarchy of surgical stability in orthognathic surgery: overview of systematic reviews", International Journal of Oral and Maxillofacial Surgery, 2019

Publication

<1 %

51

Reyneke, J.P.. "Postoperative skeletal stability following clockwise and counter-clockwise rotation of the maxillomandibular complex compared to conventional orthognathic treatment", British Journal of Oral & Maxillofacial Surgery, 200701

Publication

<1 %

52

Theo J. M. Hoppenreijis. "Long-term evaluation of patients with progressive condylar resorption following orthognathic surgery", International Journal of Oral and Maxillofacial Surgery, 12/1999

Publication

<1 %

53

Vanessa Álvares de Castro Rocha, Antonio Irineu Trindade Neto, Iêda Margarida Crusoé Rocha Rebello, Gustavo Mota Mascarenhas de Souza et al. "Skeletal stability in orthognathic surgery: evaluation of methods of rigid internal fixation after counterclockwise rotation in patients with

<1 %

class II deformities", British Journal of Oral and Maxillofacial Surgery, 2015

Publication

54

Y. Sirin, S. Yildirimturk. "Ex vivo biomechanical stability of sagittal split osteotomy with lingual bad splits", Journal of Stomatology, Oral and Maxillofacial Surgery, 2019

Publication

<1 %

55

link.springer.com

Internet Source

<1 %

56

medworm.com

Internet Source

<1 %

57

www.neca.re.kr

Internet Source

<1 %

58

www.reumatologiaclinica.org

Internet Source

<1 %

59

Tsang, W.M.. "Cephalometric characteristics of anterior open bite in a southern Chinese population", American Journal of Orthodontics & Dentofacial Orthopedics, 199802

Publication

<1 %

60

Dicker, G.J.. "Adaptation of lateral pterygoid and anterior digastric muscles after surgical mandibular advancement procedures in different vertical craniofacial types: A magnetic resonance imaging study", Oral

<1 %

Surgery, Oral Medicine, Oral Pathology, Oral Radiology and Endodontology, 200806

Publication

61

Ewa Zawiślak, Szymon Przywitowski, Anna Olejnik, Hanna Gerber, Paweł Golusiński, Rafał Nowak. "Current Trends in Orthognathic Surgery in Poland—A Retrospective Analysis of 124 Cases", Applied Sciences, 2021

Publication

<1 %

Exclude quotes On

Exclude matches < 5 words

Exclude bibliography On