

Distally based hemisoleus flap for soft tissue defect closure following chronic osteomyelitis of the distal tibia: A case report

by Petrus Johan

Submission date: 07-Nov-2021 05:51AM (UTC+0700)

Submission ID: 1695019557

File name: sed_hemisoleus_flap_for_soft_tissue_defect_closure_following.pdf (5.36M)

Word count: 2573

Character count: 14459



ELSEVIER

Contents lists available at ScienceDirect

International Journal of Surgery Case Reports

journal homepage: www.elsevier.com/locate/ijscr

Case report

Distally based hemisoleus flap for soft tissue defect closure following chronic osteomyelitis of the distal tibia: A case report

Muhammad Phetrus Johan^{*}, Ira Nong, Ruksal Saleh, Erich Svante Subagio^{*},
Ahmad Perdana Asy'arie, Maxmillian Alexander Kawilarang

Department of Orthopaedics and Traumatology, Dr. Wahidin Sudirohusodo General Hospital - Faculty of Medicine Hasanuddin University, Makassar, Indonesia



ARTICLE INFO

Keywords:

Chronic osteomyelitis
Defect closure
Hemisoleus flap
Pedicled flap
Case report

ABSTRACT

Introduction and importance: Chronic osteomyelitis often needs extensive debridement that leaves a gap and needs soft tissue reconstruction procedure. The use of pedicled versus free flap to reconstruct soft tissue following surgical debridement has long been debated. Pedicle flap is more favored by many surgeons for the distal third tibia, mainly due to its lower failure rate.

Case presentation: We report a 33-year-old man with eight years of chronic osteomyelitis treated with surgical debridement at the distal third tibia, leaving a 5 cm × 6 cm soft tissue defect with exposed bone. Against the common preference, we performed a distally based hemisoleus flap (pedicled flap) covered with a split thickness skin graft. No signs of flap/graft rejection were observed during follow-up, and the patient was able to return to work four months following the surgery. No limitation in patient's daily activity upon two years follow up.

Clinical discussion: Preservation of critical perforators is essential during the elevation of the flap. The knowledge and application of the vascularity and angiosome principles are crucial in designing this type of flap, as some anatomical variations do exist. Meticulous tissue handling is required to support the basic knowledge of the lower limb vascular system.

Conclusion: Distally based hemisoleus flap is a reasonable option for soft tissue defect following chronic osteomyelitis of the distal tibia.

1. Introduction

Chronic osteomyelitis may be associated with extensive tissue infection. Treatment typically includes a combination of systemic and local infection control. While systemic control is often associated with a prolonged course of antibiotic therapy, local control is often associated with either a single or series of surgical procedures; when the infected limb is considered unsalvageable, amputation may become the only treatment choice. The basic principles of surgery are to obtain adequate microbiological sampling, perform a complete removal of all macroscopically devitalized tissue and infected implants (introducing healthy local blood flow is crucial, most antibiotic regimens will fail without neovascularization [1]), manage dead space, ensure adequate skeletal stabilization, and provide immediate wound cover [2].

These surgical procedures often involve extensive removal of infected/dead tissue that might cause the significant defect, thus requiring

surgical reconstruction procedure. Flap might be chosen for this, and in most cases, the necessity of a flap can be predicted at the initial assessment [2]. Soft tissue flap has some essential roles in facilitating the delivery of antibiotics and innate host immunity and obliterating dead space following the surgical excision [1].

There have been many circulating debates over the use of pedicled versus free flap to provide soft tissue coverage following extensive debridement in tibia osteomyelitis. We aim to demonstrate that a distally based hemisoleus flap is a feasible option to reconstruct soft tissue defects at the distal third of the medial tibia. This work has been reported in line with Surgical Case Report (SCARE 2020) criteria [3].

2. Presentation of case

A 33-year-old man presented to our clinic with eight years of recurrent infection and purulent discharge at his left lower leg following

^{*} Corresponding authors at: Department of Orthopaedics and Traumatology, Dr. Wahidin Sudirohusodo General Hospital - Faculty of Medicine Hasanuddin University, Jl. Perintis Kemerdekaan Km 10, Hasanuddin University Hospital 3rd Floor, Makassar, Indonesia.

E-mail addresses: muhpjo@gmail.com (M.P. Johan), erich.subagio@gmail.com (E.S. Subagio).

<https://doi.org/10.1016/j.ijscr.2021.106437>

Received 28 July 2021; Received in revised form 19 September 2021; Accepted 19 September 2021

Available online 21 September 2021

2102-2612/© 2021 The Authors. Published by Elsevier Ltd on behalf of IJS Publishing Group Ltd. This is an open access article under the CC BY-NC-ND license

<http://creativecommons.org/licenses/by-nc-nd/4.0/>.

a Gustilo grade II open fracture of the tibia and fibula (Fig. 1). He has had several series of antibiotic treatments and non-operative wound care at the local health facility prior to his visit. Radiographic imaging confirmed union at the fracture site, and the presence of involucrum and sclerotic rim with regional osteopenia highly indicate osteomyelitis (Fig. 5).

Under general anesthesia, the patient was laid in the supine position. The operation was done by two orthopedic surgeons assisted with two residents of general orthopedic surgery. We performed the surgical debridement, sequestrectomy with a bone guttering procedure. A wide area of skin and soft tissue necrosis required us to perform a necrotomy, thus leaving a 5 cm × 6 cm defect with exposed bone. Pus and soft tissue sample were taken for culture and histopathological examination. Histopathologic evaluation revealed chronic infection with no signs of neoplastic/malignant transformation. The incision was extended proximally toward the crease between the medial head of gastrocnemius and soleus muscle and distally toward the medial malleolus. We separated the soleus muscle from the flexor digitorum longus muscle (anteriorly) and medial gastrocnemius muscle (posteriorly) by blunt dissection. Meticulous care was taken to preserve both the greater saphenous vein and saphenous nerve (superficial) and posterior tibial vascular and tibial nerve (deep). A sharp dissection was made at the middle third of the medial soleus muscle to ensure a good rotation arc and preserve the secondary vascular pedicle. The soleus muscle was then transposed and fixed into the defect. We harvested a split thickness skin graft from the ipsilateral anterior thigh. The graft was prepared with a diamond-shaped mesh pattern and covered with tied-over padded gauze (Fig. 3). The patient showed good adherence to the treatment regimen. Pus production ceased along with the improved wound healing and no sign of flap and graft necrosis.

We noticed a hyperpigmented area on the skin graft after two years of follow-up with no exposed bone nor soft tissue defect. There is no limitation in the patient's daily activity, and he has been able to return to work four months following the surgery (Fig. 4).

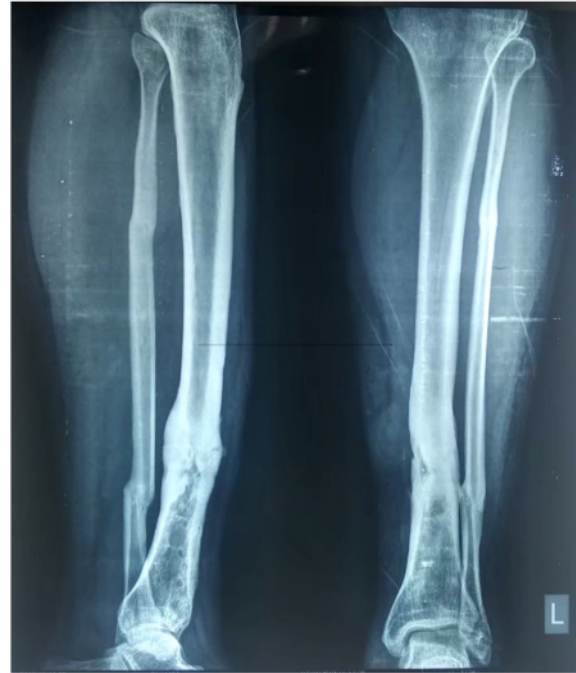

Fig. 2. Plain radiograph of the patient.

3. Discussion

Chronic osteomyelitis is sometimes challenging to manage. Historically, it is often associated with high rates of recurrence and secondary amputation. Treatment for chronic osteomyelitis is complex, multifaceted, and usually requires multidisciplinary

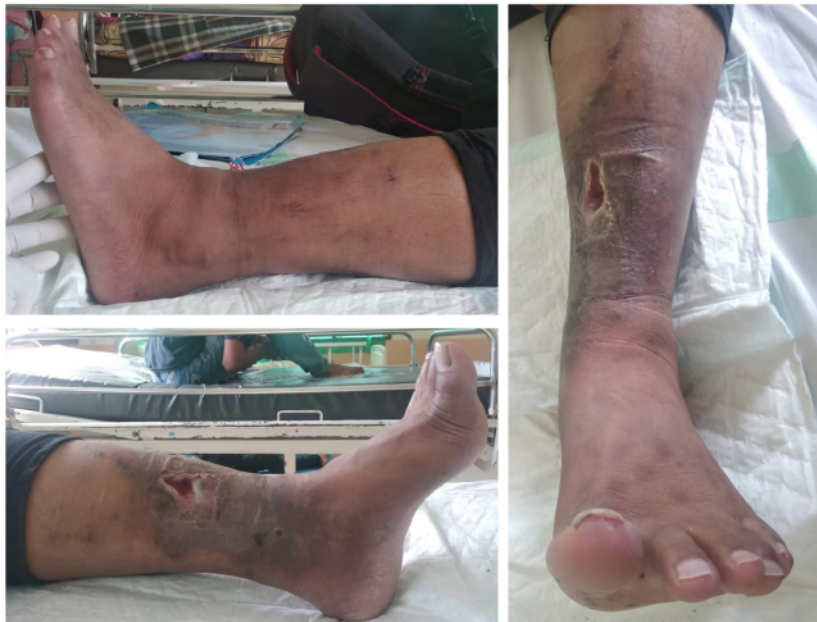

Fig. 1. The infected wound at the medial distal third of the left crus with active pus production.

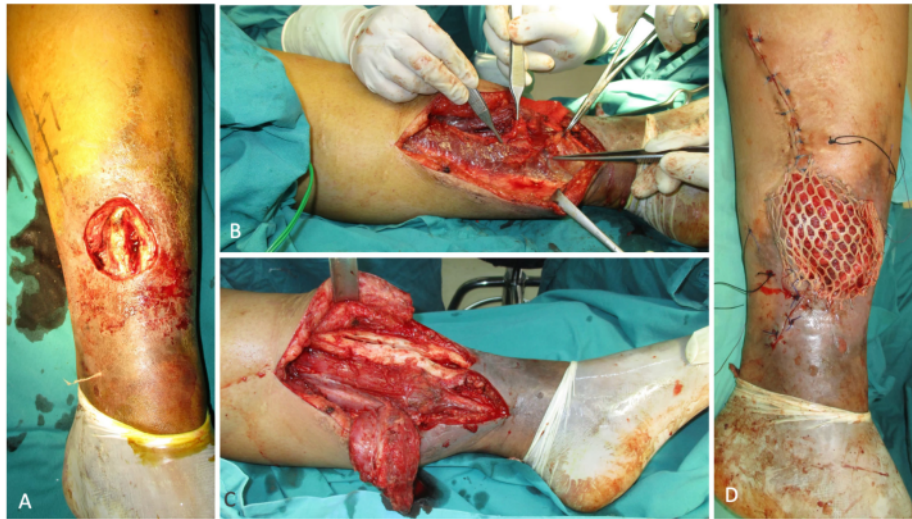

Fig. 3. A 5 cm × 6 cm of soft tissue defect with exposed tibial bone intraoperative (A). Meticulous dissection and identification of pedicle arteries for soleus muscle (B-C). Split thickness skin graft with diamond-shaped mesh pattern is applied onto muscle flap.

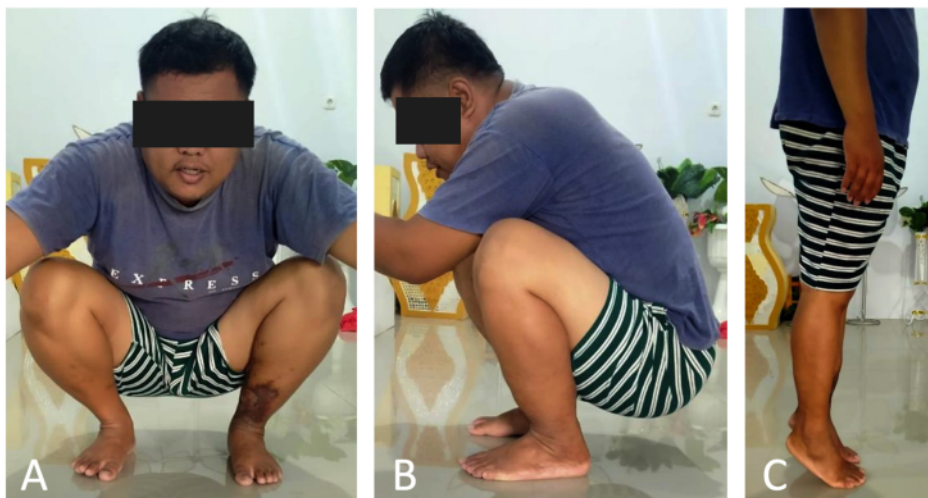


Fig. 4. No limitation in daily activity following the surgery.

15 approaches, including surgical debridement, skeletal or soft tissue reconstruction, and local/systemic antimicrobial control [2].

Surgery is the cornerstone of effective management for chronic osteomyelitis [2]. It should be able to obtain adequate microbiological sampling, perform a complete removal of all macroscopically devitalized tissue and infected implants (introducing healthy local blood flow is crucial, as most antibiotic regimens will fail without neovascularization [1]), manage postsurgical dead space, ensure adequate skeletal stabilization, and provide immediate wound cover [2].

Following the excision of osteomyelitis, soft tissue reconstruction in the form of a tissue flap may be required [2]. A well-vascularized soft tissue coverage with rapid healing will provide a physical and microbiological barrier between the bone and the external environment, including contact with nosocomial microorganisms [2]. A single-stage procedure including bone procedure (i.e., excision) and soft tissue reconstruction should be performed whenever possible, as will it allow

rapid tissue coverage and is associated with earlier bone healing, reduced infection, and shorter hospital time [2].

There have been many debates regarding the use of pedicled versus free flap. Some studies advocated free flaps in the middle and distal third of the tibia due to the limited local tissue and to avoid adding injury to the damaged area [2,6]. The use of pedicled flap in the lower distal third of the tibia is often associated with unacceptably high rates of failure, especially in patients with multiple comorbidities affecting vascular function (venous insufficiency, peripheral arterial disease, diabetes mellitus, smoker, etc.) [2,4].

Gokalp et al. [4] cited some studies that reported the technique of bone guttering surgery followed by transposed muscle flap showed no recurrence after 12 years follow up in chronic osteomyelitis patients. In his study, he reported no recurrence was observed after two years of follow-up. Tobin was the first surgeon who reported the use of distally based hemi-soleus flap in 1984, advocated the refinements in local tissue

reconstruction due to some variability in distal perforators and retrograde blood supply. Yet, it never gains popularity due to concerns over its reliability [6].

Although there are some variabilities in the vascular structures, distally based hemisoleus flap has been reported to show successful outcomes by some other researchers [6]. As one of the surgeons who advocated using a distally based hemisoleus flap in the distal third leg, Pu [7] emphasized the importance of preserving "critical perforators" during the elevation of a viable flap. These "critical perforators" which supply the inferomedial aspect of the soleus muscle, arise distally from the posterior tibial artery just above the level of the medial malleolus (Fig. 5 [6]).

In a distally based hemisoleus flap, the muscle can be rotated up to about two-thirds of its length and is best used to cover the anterior and distal part of the tibia [8]. The knowledge and application of the vascularity and angiosome principles are crucial in designing this type of flap, as one with a lack of this knowledge will be tempted to use a more significant portion of the flap to increase the rotation arc or the bulk, thus results in distal muscle problems and leads to complications as described by prior studies regarding the reliability of this flap [6]. According to Mathes and Nahai classification, the blood supply for soleus muscle is type II, which means it is as the dominant and the minor pedicles. Proximally, the dominant/major pedicles arise from the posterior tibial artery $\pm 3-4$ centimeters (cm) distal to soleus arcade. Distally, the minor pedicles are located between 6-7 cm and 11-13 cm proximal to the medial malleolus [8]. Prasad [9] studied 38 adults lower limbs and found that the mean distance of the last pedicle of a posterior tibial artery that supplies distal part of medial hemisoleus is 29.9 ± 4.7 cm from the imaginary horizontal line that crosses the head of the fibula at the level of the most proximal attachment of soleus muscle, with the range of 20.1-37.5 cm. Some anatomical variations do exist. Therefore meticulous tissue handling is required to support the basic knowledge of the lower limb vascular system.

We prefer to use the medial hemisoleus muscle flap over the whole soleus muscle as the former can provide a larger arc of rotation and has a lesser functional impact on the loss of plantar flexion [7]. The use of pedicled flap is encouraged in a smaller size wound typically less than 50 cm^2 [6,7]. Schierle et al. described that pedicled flap had shown advantages over free flap in terms of donor-site morbidity, the less necessity of microsurgery equipment, and more cost effective [6].

4. Conclusion

Distally based hemisoleus flap is a reasonable option for soft tissue defect following chronic osteomyelitis of the distal tibia.

Consent

Written informed consent was obtained from the patient for publication of this case report and accompanying images. A copy of the written consent is available for review by the Editor-in-Chief of this journal on request.

Provenance and peer review

Not commissioned, externally peer-reviewed.

Ethical approval

All investigators ensure that the conduct of this study is in accordance with the ethical standards of their respective institutions as laid down in the 1964 Declaration of Helsinki.

Funding

The research did not receive any specific grant from funding agencies

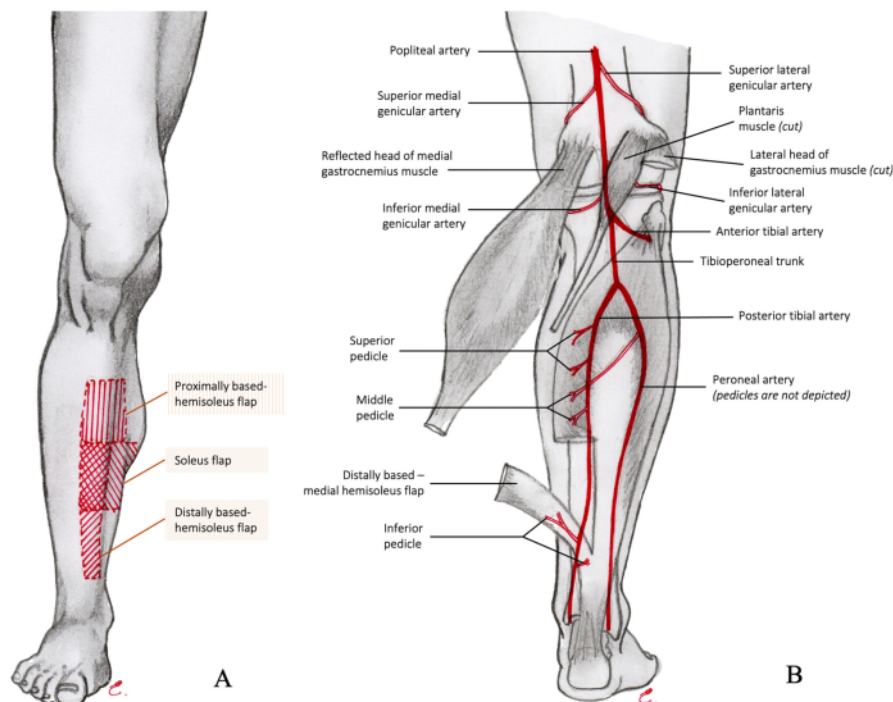


Fig. 5. Schematic image shows area coverage by different types of soleus muscle flap (A). Schematic image of vascular anatomy of medial distally based hemisoleus flap (B).

in the public, commercial, or not-for-profit sectors.

Guarantor

Muhammad Phetrus Johan, MD., PhD.

18

Research registration number

Not applicable.

Credit authorship contribution statement

MPJ contributed to perform the surgery, conceptualization, methodology, clinical data investigation, curation and interpretation; IN contributed to perform the surgery, conceptualization, methodology, clinical data investigation, curation and interpretation; RS contributed to perform the surgery, conceptualization, methodology, clinical data investigation, curation and interpretation; ESS contributed to assist the surgery, clinical data interpretation; APA contributed to assist the surgery, clinical data interpretation; MAK contributed to clinical data curation and interpretation. All authors: writing – original draft, review, editing and approved the final manuscript for publishing.

9

Declaration of competing interest

The authors declare that there are no conflicts of interest regarding the publication of this article.

Acknowledgment

None.

References

- [1] B. Parsons, E. Strauss, Surgical management of chronic osteomyelitis, *Am. J. Surg.* 188 (July) (2004) 31–33, [https://doi.org/10.1016/S0002-9610\(03\)00292-7](https://doi.org/10.1016/S0002-9610(03)00292-7).
- [2] J.K.K. Chan, J.Y. Ferguson, M. Scarborough, M.A. McNally, A.J. Ramsden, Management of Post-Traumatic Osteomyelitis in the lower limb: current state of the art, *Indian J. Plast. Surg.* 52 (2019) 62–72.
- [3] R.A. Agha, T. Franchi, C. Sohrabi, G. Mathew, A. Kerwan, The SCARE 2020 guideline: updating consensus Surgical Case Report (SCARE) guidelines, *Int. J. Surg.* (2020), <https://doi.org/10.1016/j.ijsu.2020.10.034>.
- [4] M.A. Gokalp, S. Guner, M.F. Ceylan, A. Dogan, A. Sebik, Results of treatment of chronic osteomyelitis by “gutter procedure and muscle flap transposition operation”., *Eur. J. Orthop. Surg. Traumatol.* (2013) <https://doi.org/10.1007/s00590-013-1196-z>.
- [5] J.M. Franken, P. Hupkens, P.H.M. Spauwen, The treatment of soft-tissue defects of the lower leg after a traumatic open Tibial fracture, *Eur. J. Plast. Surg.* 33 (2010) 129–133, <https://doi.org/10.1007/s00238-010-0405-9>.
- [6] C.F. Schierle, V. Rawlani, R.D. Galiano, J.Y.S. Kim, G.A. Dumanian, Improving outcomes of the distally based hemisoleus flap: principles of angiosomes in flap design, *PRSJ.* 1748–1754 (2008), <https://doi.org/10.1097/PRS.0b013e3181a65a74>.
- [7] L.L.Q. Pu, Further experience with the medial hemisoleus muscle flap for soft-tissue coverage of a Tibial wound in the distal third of the leg, *PRSJ.* 2024–2028 (2008), <https://doi.org/10.1097/PRS.0b013e318171240c>.
- [8] D.A. Volgas, Y. Harder, Manual of Soft-Tissue Management in Orthopaedic Trauma, AO Foundation, Davos Platz, Switzerland, 2011, <https://doi.org/10.1055/b-002-85481>.
- [9] V. Prathapamchandra, L.V. Prabhu, M.M. Pai, B.V. Murlimanju, R. Vadgaonkar, Arterial supply to the soleus muscle: an anatomical study with emphasis on its application in the pedicle flap surgery, *Surg. Radiol. Anat.* 37 (9) (2015) 1055–1061, <https://doi.org/10.1007/s00276-015-1485-9>.

Distally based hemisoleus flap for soft tissue defect closure following chronic osteomyelitis of the distal tibia: A case report

ORIGINALITY REPORT

22%

SIMILARITY INDEX

14%

INTERNET SOURCES

19%

PUBLICATIONS

5%

STUDENT PAPERS

PRIMARY SOURCES

1	Submitted to Logan University Student Paper	2%
2	www.dspace.uce.edu.ec Internet Source	2%
3	"10 Wound closure and coverage techniques (III)", Georg Thieme Verlag KG, 2011 Publication	2%
4	academic.oup.com Internet Source	2%
5	"Operative Dictations in Plastic and Reconstructive Surgery", Springer Science and Business Media LLC, 2017 Publication	1%
6	Jae Bum Park, Song Am Lee, Yo Han Kim, Woo Surng Lee, Jae Joon Hwang. "Extramedullary Hematopoiesis Mimicking Mediastinal Tumor in a Patient with Hereditary Spherocytosis: Case report", International Journal of Surgery Case Reports, 2017 Publication	1%

7	Zeynep Unluer, Yazan Al-Ajam, Sammy Al-Benna. "Functional Outcome After Reconstruction of Traumatic Soft Tissue Defects in the Lower Half of the Leg With Distally Based Medial Hemisoleus Muscle Flaps", <i>Annals of Plastic Surgery</i> , 2018 Publication	1 %
8	Lee L.Q. Pu. "Locoregional Flaps in Lower Extremity Reconstruction", <i>Clinics in Plastic Surgery</i> , 2021 Publication	1 %
9	www.medrxiv.org Internet Source	1 %
10	"42 Soleus Muscle Flap", Georg Thieme Verlag KG, 2021 Publication	1 %
11	link.springer.com Internet Source	1 %
12	Jose Antonio Delgado Perez, Pedro Rodriguez, Michael D. Liette, Suhail Masadeh. "Medial Hemisoleus Flap for Middle Third of the Tibia Defects", <i>Clinics in Podiatric Medicine and Surgery</i> , 2020 Publication	1 %
13	Submitted to Udayana University Student Paper	1 %

14 Vani Prathapamchandra, Latha V. Prabhu, Mangala M. Pai, B. V. Murlimanju, Rajanigandha Vadgaonkar. "Arterial supply to the soleus muscle: an anatomical study with emphasis on its application in the pedicle flap surgery", Surgical and Radiologic Anatomy, 2015
Publication

15 doaj.org
Internet Source

16 Ping Song, Lee L. Q. Pu. "The Soleus Muscle Flap", Annals of Plastic Surgery, 2018
Publication

17 publish.kne-publishing.com
Internet Source

18 Brahmana Askandar Tjokroprawiro. "Large traumatic vulvar hematoma managed with a simple incision: A case report", International Journal of Surgery Case Reports, 2021
Publication

19 Ehab Mostafa Mohamed El Zawawy, Nancy Mohamed El Sekily. "An anatomical study of the blood supply of the soleus muscle in humans", Alexandria Journal of Medicine, 2012
Publication

20 Lee L. Q. Pu. "Further Experience with the Medial Hemisoleus Muscle Flap for Soft-Tissue Coverage of a Tibial Wound in the Distal Third of the Leg", Plastic and Reconstructive Surgery, 06/2008
Publication <1 %

21 docksci.com
Internet Source <1 %

22 Dilraj Singh Bhullar, Saravana Vail Karuppiah, Ahmed Aljawadi, Tess Gillham, Omar Fakhri, Khadija Khamdan, Anand Pillai. "Local flaps vs. free flaps for complex lower limb fractures: Effect of flap choice on patient-reported outcomes", Journal of Orthopaedics, 2020
Publication <1 %

23 abjs.mums.ac.ir
Internet Source <1 %

24 koreascience.or.kr
Internet Source <1 %

Exclude quotes On

Exclude matches < 5 words

Exclude bibliography On